

Neglected Bronchial Foreign Body in a Child Simulating a Calcified Mass Lesion: Challenging Computed Tomography Diagnosis

Ahmed A Bahnassy* and Abdul Basset Diab**

**Department of Radiology, Qassim University and*

***Maternity and Children Hospital, Buraidah, Saudi Arabia.*

Correspondence:

Dr. Ahmed A. Bahnassy.

College of Medicine, Qassim University,

PO Box 6655, Buraidah 51452

e-mail: aatteya2001@yahoo.com

Introduction

The well known habit of children to place objects in mouth frequently leads to impaction of foreign body in tracheobronchial tree. It is one of the leading causes of accidental home deaths in children under 6 years. ⁽¹⁾ The major issue involves the accurate diagnosis, speedy and safe retrieval of the foreign body. The accurate diagnosis may elude even the sophisticated physician because often the initial choking incidents are not witnessed and the delayed symptoms may mimic other common conditions, such as asthma, pneumonia, or upper respiratory tract infections. ⁽¹⁻³⁾ The most common foreign bodies aspirated are food products - peanuts, beans and seeds. ^(1,4) Beans and seeds absorb water over time and with subsequent swelling rapidly change from partial to complete bronchial obstruction. Some organic foreign bodies cause surrounding tissue reaction, and this may result in a condition known as arachidic bronchitis. ⁽³⁾

Case Report

This patient is a boy 7 years old, presenting to Maternity and Children Hospital, Buraidah, Saudi Arabia, with recurrent unresolved pneumonia. Due to the long history of the patient and abnormal X-ray findings (not shown) CT was requested.

CT revealed a partially calcified mass at the region of right hilum, causing complete obstruction of bronchus intermedius (Figure 1), and subsequent collapse of right middle and lower lobes (Figure 2 and 4).

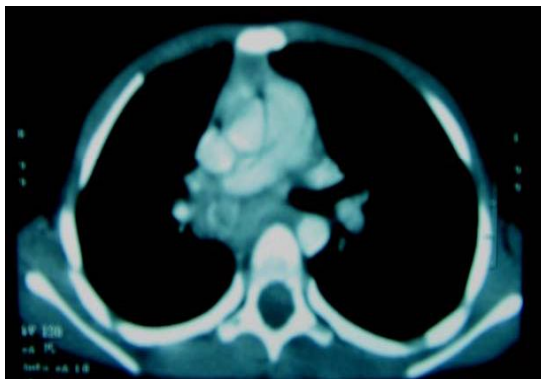


Fig (1). Pre-contrast CT chest showing a right hilar rounded "mass" with rim calcification

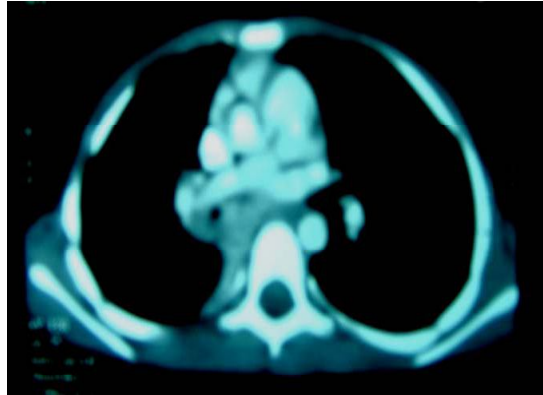


Fig (2). Post contrast CT showing a very narrowed bronchial residual lumen with paraspinal lung collapse.

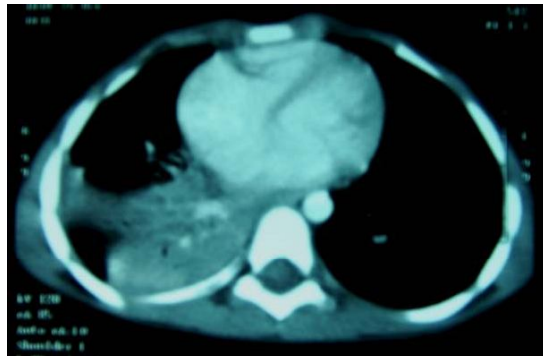


Fig (3). Post contrast CT showing drowned lung appearance and mucus bronchogram sign

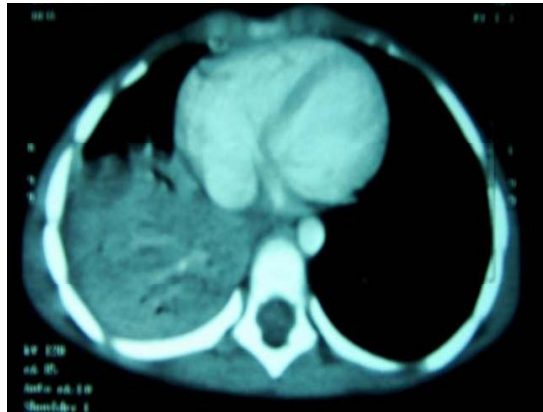

Fig (4). Combined right middle and lower lobes collapse with CT arteriogram sign

The collapsed lung showed "mucous bronchogram sign" denoting bronchial obstruction, as well as CT arteriogram sign (Figures 3 and 4). The possibility of tuberculous lymphadenopathy was considered; nevertheless all laboratory investigations for TB were negative.

More ominous possibility including calcified neoplastic lesions was postulated, although rare in this age group, and hence bronchoscopy was ordered.

Rigid Bronchoscopy revealed a localized, vascular, easily bleeding, non infiltrating mass lesion occluding the bronchus intermedius. A biopsy was taken from this mass.

The result of biopsy revealed inflammatory granulation tissue.

This is at that time that the patient's father revealed a history of aspiration of a crackable plant seed (known in Saudi Arabia as *fofos*) – wherein the boy suffered severe choking before aspirating this seed. That incident happened 3-4 months ago, enough so to be forgotten initially by the parents, who thought it was a trivial accident.

Discussion

It is well known that a long-standing foreign body in the bronchial tree, even if it is very small, may result in total obstruction by edema or secretions. Wiseman⁽⁴⁾ comparing patients with early and late diagnosis found that in the early group half had evidence of air trapping, and one sixth had atelectasis or consolidation. The rationale behind this large number of patients with atelectasis or consolidation seems to be a long standing foreign body in the tracheobronchial tree.

No history of foreign body aspiration can be elicited in 14% of cases of foreign body aspiration. This shows the importance of high index of suspicion. Hoeve *et al*⁽⁵⁾ who studied the diagnostic value of signs and symptoms due to foreign body found choking and coughing to be very sensitive features (81% and 71% respectively).

Late complications of vegetable foreign body are grave, as they not only increase in size but also cause chemical reaction with bronchial secretions.⁽¹⁾

Arachidic bronchitis, severe form of bronchitis resulting from inhalation of vegetable foreign bodies can elicit a so intense inflammatory reaction, and granuloma formation that it can mimic malignancy.

The constituent of the foreign body may present radiologically as areas of calcifications which can complicate further the picture - in absence of clear history of foreign body aspiration.

This case highlights - in addition to the known picture of atelectasis associated with bronchial foreign body - the peculiar radiological presentations with which the foreign body can show itself in our daily practice.

References

1. Bhavana B. Lakhkar, Pushpa Kini, Vijaya Shenoy and Nalini Bhaskaranand . Indian Pediatrics 2000;37: 193-195
2. Aytaac A, Yurdakul Y, Ikizler C et al. Inhalation of foreign bodies in children. J Thorac Cardiovasc Surg 1977; 74: 145-51.
3. McGuirt WF et al. Tracheobronchial foreign bodies. Laryngoscope 1988; 98: 615.
4. Wiseman NE. The diagnosis of foreign body aspiration in childhood. J Pediatr Surg 1984; 19: 531-35.
5. Hoeve LJ, Rombout J, Pot DJ. Foreign body aspiration in children. The diagnostic value of signs and symptom and preoperative examination. Clin Otolaryngol 1993; 18: 55-57.