

## Role of B-Scan Ultrasonography in pre-operative cataract patients

**MANZOOR A QURESHI**

Department of Ophthalmology  
Liaquat University Eye Hospital  
Hyderabad, Pakistan

**KHALIDA LAGHARI**

Department of Radiology  
Liaquat University Hospital  
Hyderabad, Pakistan

### Abstract

**Objective:** To visualize the posterior portion of eye globe in dense cataract patients with B scan ultrasound, to find out any posterior segment lesion in such pre-operative cases.

**Research Design and Methods:** We performed diagnostic B-scan ultrasound on 750 cataract patients before surgery. This was a prospective diagnostic study which was conducted in the Department of Ophthalmology, Liaquat University Eye Hospital, Hyderabad Sind, Pakistan from January 2007 to July 2007. Detailed history and some basic eye examination techniques, like slit lamp and tonometry were done in two groups of patients, traumatic (71) and non traumatic (679). Patients in the age range of 1 to 79 years of both sexes were included. Patients having already posterior segment lesions and those who had previous history of ocular surgery were excluded from the study. An ultrasound machine Nidek Echo Scan Model US-3300 with a probe of direct contact was used.

**Results:** Out of 750 patients, 90 patients had posterior segment lesions. Among traumatic group of 71 patients, 39 (55%) had positive posterior segment lesions, while in the non traumatic group of 679 patients, only 51 (7%) cases had positive posterior segment lesions. Out of the 90 positive cases, 25 (3%) had retinal detachment, 14 (2%) had posterior vitreous detachment, 24 (3%) had vitreous hemorrhage, 12 (2%) were asteroid hyalosis, while posterior staphyloma and intra-ocular foreign body were found with the frequency of 9 (1.2%) and 6 (1%), respectively.

**Conclusion:** We concluded that two dimensional B-scan ultrasound can be one of the diagnostic tool for the detection of hidden posterior segment lesions and can be performed routinely in pre-operative cataract patients, as this would help in surgical planning. In cases, where a two dimensional B-scan is not sufficient or helpful a three dimensional ultrasound would be justified.

**Key words:** Ultrasonic A-Scan B-Scan, Cataract, Posterior Segment lesion

Corresponding Author: *Dr. Manzoor Ahmed Qureshi*  
*Assistant Professor Ophthalmology*  
*Department of Optometry*  
*College of Applied Medical Sciences*  
*Qassim University*  
*P.O.Box 6699.Buraidah 51452*  
*Kingdom of Saudi Arabia.*  
*E-mail: [drmaqureshi@hotmail.com](mailto:drmaqureshi@hotmail.com)*  
*Cell No:0568248309*

## INTRODUCTION

Ultrasound is an acoustic wave that consists of an oscillation of particles within a medium. Ultrasound was first used in ophthalmology in 1956 by the American ophthalmologists, Mundt and Hughes.<sup>1</sup> They used A-scan mode to evaluate an intraocular tumor. B-scan was introduced in ophthalmic practice by Baum and Greenwood in 1958.<sup>2</sup> Both A-scan and B-scan techniques are important for the diagnosis of posterior segment lesion. B (Brightness) mode is useful for a better demonstration of the shape and topographic relationship of lesions in the posterior segment.<sup>3</sup> B-scan provides cross sectional display of diseased tissues and is valuable in detecting unsuspected posterior segment diseases.<sup>4</sup> The frequency used in the diagnostic ophthalmic ultrasound for posterior segment is 8-10 MHz. Over the last 30 years ultrasonography has greatly advanced and this has enabled us to study posterior segment of the eye in the presence of opaque media.<sup>5</sup> It's most common use is in a contact mode for evaluation of the posterior segment in eyes with media opacification.<sup>6</sup> Ultrasonography is an important tool for evaluating the posterior segment in eyes with opaque media and provides a method of assessing the structural changes in the posterior segment of the eye in such patients.<sup>7,8</sup> The most frequent findings of posterior segment lesions associated with perforating and blunt trauma and also without trauma were recorded on B-scan ultrasound, like retinal detachment, vitrous haemorrhage, intraocular foreign body, neoplasia and posterior vitrous detachment.<sup>9,10</sup> The purpose of the study was to visualise the status of posterior segment with the diagnostic tool of B-scan ultrasound in pre-operative dense cataract patients, to find out any posterior segment lesion in such cases.

## PATIENTS AND METHODS

This was a prospective diagnostic study which was confined to the assessment of posterior segment lesion at pre-operative stage. Diagnostic B-scan ultrasound on 750 cataract patients before

surgery were performed from January to July 2007 in the Department of Ophthalmology, Liaquat University Eye Hospital, Hyderabad Sind, Pakistan. Detailed history and some eye examination, like slit lamp and tonometry were done in two groups of patients, traumatic and non traumatic. Patients in the age range of 1 to 79 years of both sexes were included. Patients having already posterior segment lesions and those who had previous history of ocular surgery were excluded from the study. Patients were briefly explained the procedure for their co-operation. Nidek Echoscanner Model US-3300 with a probe of direct contact was used. Ultrasonic probe was placed over the globe of the eye with closed lid after application of the gel and then antero-posterior, longitudinal and transverse views of B-scan along with A-scan were taken. High gain (80 to 90dB) and low gain (60 to 70dB) sensitivity were selected during ultrasonography.

## RESULTS

Out of a total of 750 patients, 71 (9.47%) cases were of post-traumatic cataract and 679 (90.53%) were non-traumatic cataract. The age range was 1 to 79 years in both sexes (Table-1).

In the non-traumatic cataract group of patients, more than half (72.16%) were in the range of 50 to 69 years of age, this is the age group where senile cataract is common. The mean (standard deviation) age was 54 (8.25) years, out of which, females were 286 (42.12%) and males were 204 (30.04%). In traumatic cataract group of mild, blunt and penetrating in nature, most of the patients (49.29%) were in the range of 10 to 19 years, the mean (standard deviation) age was 13.7 (2.73) years, the age group where trauma is more common; 29 patients (40.84%) were males, 6 patients (8.45%) were females (Table-1).

Of the total 750 patients in the study, 90 (12%) patients had ultrasonically detectable posterior segment lesions (Table-2), 51 (7%) cases belonged to the non-traumatic cataract group and 39 (55%) to traumatic cataract group.

Out of the 90 positive cases, 25 (3%) had retinal detachment (Fig-1), 14 (2%) had posterior vitreous detachment (Fig-2), 24 (3%) had vitreous hemorrhage (Fig-3), 12 (2%) were asteroid hyalosis (Fig-4), while posterior staphyloma (Fig-6) and intra-ocular foreign body (Fig-5) were found with the frequency of 9 (1.2%) and 6 (1%), respectively (Table-2).

## DISCUSSION

Over the last 30 years, ultrasonography has greatly advanced which has enabled us to study posterior segment of the eye even in the presence of opaque media like dense cataract. It can also be used to detect lesions in the anterior segment and in the orbit, but it's most common use is to study the abnormalities in the posterior segment.

Posterior globe of a total of 750 patients were examined under B-scan ultrasound in 1-79 years old patients, divided into two groups. Majority of the patients (90.53%) belonged to the non traumatic cataract group and a small number (9.47%) to traumatic cataract group. Similar groups in different age ranges have also been discussed in other studies.<sup>11-13.</sup>

Trauma, either blunt or penetrating, not only damages the anterior segment but can also cause damage to the posterior segment. In traumatic cataract group, almost half (49.29%) of the patients were 10-19 years old, the age range when children are more active and involved in outdoor games and other activities.<sup>14-15.</sup>

Findings of posterior segment lesions (13.07%) in this study were similar to other published studies.<sup>16-17</sup> Out of 13.07% of patients, 8.64% patients were in non-traumatic cataract group and 54.93% patients in traumatic cataract group. Ali and Rehman reported posterior segment lesions in 11% non traumatic cataract patients and in 65.85% patients with traumatic cataract.<sup>11</sup>

Retinal detachment (1.47%) in non traumatic cataract patients was and (21.12%) in traumatic cataract patients was similar to reported by Ali and Rahman<sup>11</sup> who found retinal detachment 3.3% in non traumatic cataract and 29.26% in traumatic cataract patients; and in another study 22.5% was

noted in traumatic cataract group.<sup>12</sup> Posterior vitreous detachment (PVD) in traumatic cataract patients was 9.86% and in non-traumatic cataract patients was 1%, closer to an earlier report of 1.46% in non-traumatic cataract patients.<sup>11</sup> Vitreous hemorrhages were present in 15.49% traumatic cataract patients and 1.91% in non-traumatic cataract patients. Other investigators reported vitreous hemorrhage in traumatic cataract group as 18.3% and 13%<sup>12,15</sup>, whereas in non-traumatic cases vitreous hemorrhage was present in 2.5% cases.<sup>16</sup> A lower incidence of asteroid hyalosis (1.77%) was noted in non-traumatic cataract patients as compared to that reported by Ali and Rehman (2.93%) in their study.<sup>11</sup> Intra-ocular foreign body was found in more traumatic cataract patients(8.45%) than earlier reports (4%).<sup>18</sup> Posterior staphyloma was found in almost twice as many non-traumatic cataract patients (1.32%) than reported in other studies (0.73%).<sup>11</sup>

## CONCLUSION:

We concluded that two dimensional B-scan ultrasound could be one of the diagnostic tools for the detection of hidden posterior segment lesions and can be performed routinely in pre-operative cataract patients, which would help in planning for surgical intervention. In cases, where a two dimensional B-scan is not sufficient or helpful, a three dimensional ultrasound would be justified.

## REFERENCES

1. Mundt GH, Hughes WF. Ultrasonics in ocular diagnosis. *Am J Ophthalmol.* 1956; 41: 488-98.
2. Baum G, Greenwood I. the application of ultrasonic locating technique to ophthalmology. *Arch Ophthalmol.* 1958; 60:263-79.
3. Till P, Osoining KC. Ten year study on clinical echography in intraocular disease. *Bibl Ophthalmol.* 1975; 83:49-62.
4. Hodes BL. Eye disorders: Using ultrasound in ophthalmic diagnosis. *J Postgrad Med.* 1976; 59:197-203.

5. Zafar D, Sajad AM, Qadeer A. Role of B- Scan ultrasonography for posterior segment lesions. Pak J LUMHS. 2008; 7:7-12.
6. Khan AJ. Malignant melanoma. Pak J Ophthalmol, 1985; 1:3-5.
7. Bello TO, Adeoti CO. Ultrasonic assessment in pre-operative cataract patients. Niger Postgrad Med J. 2006; 13(4):326-8.
8. Ahmed J, Shaikh FF, Rizwan A, Memon MF. Evaluation of vitro-retinal pathologies using B-scan ultrasound. Pak J Ophthalmol. 2009; 25:4.
9. Bhatia IM, Qanda A, Dayal Y. Role of ultrasonography in ocular Trauma. Indian J Ophthalmol. 1983; 31(5): 495-498.
10. Adebayo SB, Onabolu OO, Bodunde TO, Ajibode HA. Nigerian Med Pract. 2007; 52, 82-84.
11. Nzeh DA, Owoeye JF, Ademola-Popoola DS, Uyanne I. Sonographic evaluation of ocular trauma in Ilorin, Nigeria. Eur J Ophthalmol. 2006;16 (3):453-7.
12. Ali SI, Rehman H. Role of B-scan in preoperative detection of posterior segment pathologies in cataract patients. Pak J Ophthalmol 1997;13(4):108-112.
13. Butt NH, Hye A et al. Management of fire cracker injuries. Pak J Ophthalmol. 2005;21:152.
14. Javed EA, Chaudhry AA, Ahmed I, Hussain M. Diagnostic applications of B-scan. Pak J Ophthalmol. 2007;23(2):80-83.
15. Salman A, Parmar P, Vanila CG, Thomas PA, Jesudasan CA. Is ultrasonography essential before surgery in eyes with advanced cataracts. J Postgrad Med. 2006;52(1):19-22.
16. Anteby II, Blumenthal EZ, Zamir E, Waindim P. The role of preoperative ultrasonography for patients with dense cataract: a retrospective study of 509 cases. Ophthalmic Surg Lasers. 1998;29 (2):114-8.
17. Haile M, Mengistu Z. B-scan ultrasonography in ophthalmic diseases. East Afr Med J. 1996; 73(11):703-7.

**TABLE-1. AGE AND SEX DISTRIBUTION**

AGE (YEARS)	NON-TRAUMATIC CATARACT GROUP (679 pts)		TRAUMATIC CATARACT GROUP (71 pts)		TOTAL PATIENTS (750)
	MALE	FEMALE	MALE	FEMALE	
1 - 9	15 (2.21%)	20 (2.94%)	6 (8.45%)	3 (4.22%)	44 (5.87%)
10 - 19	5 (0.74%)	4 (0.59%)	29 (40.84%)	6 (8.45%)	44 (5.87%)
20 - 29	9 (1.32%)	8 (1.18%)	9 (12.68%)	3 (4.22%)	29 (3.87%)
30 - 39	4 (0.59%)	8 (1.18%)	7 (9.86%)	2 (2.82%)	21 (2.80%)
40 - 49	13 (1.91%)	32 (4.71%)	3 (4.23%)	1 (1.41%)	49 (6.53%)
50 - 59	114 (16.79%)	111 (16.35%)	2 (2.82%)	0 (0%)	227 (30.27%)
60 - 69	90 (13.25%)	175 (25.77%)	0 (0%)	0 (0%)	265 (35.33%)
70 - 79	22 (3.24%)	49 (7.22%)	0 (0%)	0 (0%)	71 (9.47%)

**TABLE-2. ULTRASOUND B-SCAN FINDINGS**

POSTERIOR SEGMENT LESION	NON-TRAUMATIC CATARACT GROUP (679 PTS)	TRAUMATIC CATARACT GROUP (71 PTS)	TOTAL PATIENTS (750)
Retinal detachment	10 (1.47%)	15 (21.12%)	25 (3.33%)
Vitreous hemorrhage	13 (1.91%)	11 (15.49%)	24 (3.2%)
Posterior vitreous detachment	7 (1.03%)	7 (9.86%)	14 (1.87%)
Asteroid Hyalosis	12 (1.77%)	0 (0%)	12 (1.6%)
Intra-ocular foreign body	0 (0%)	6 (8.45%)	6 (0.8%)
Posterior staphyloma	9 (1.32%)	0 (0%)	9 (1.2%)

Fig. 1: Ultrasonography of the globe shows a retinal detachment (arrow)

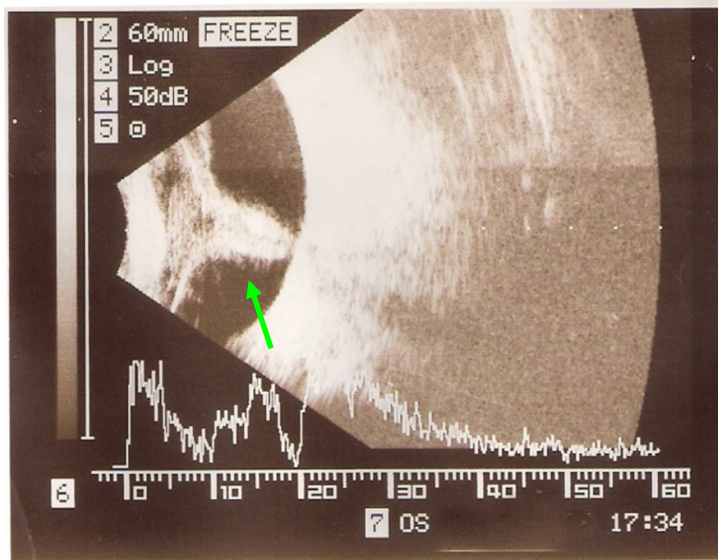


Fig. 2: Ultrasonography of the globe shows posterior vitreous detachment (arrow)

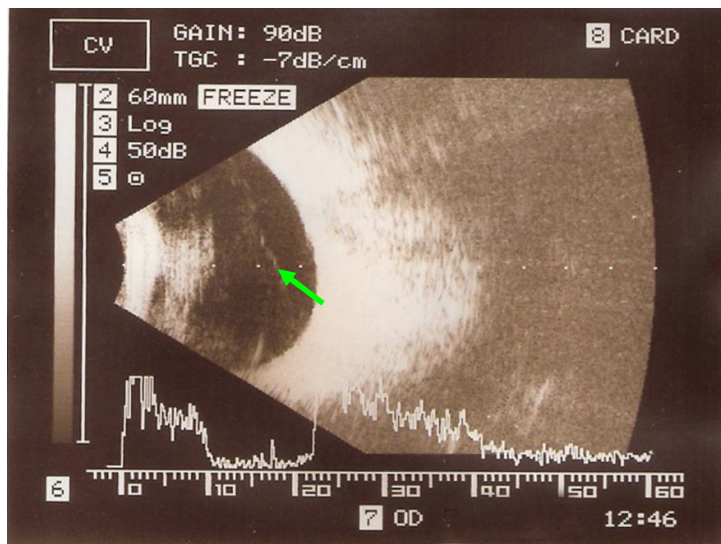


Fig. 3a: Ultrasonography of the globe shows vitreous hemorrhage in low gain sensitivity (arrow).

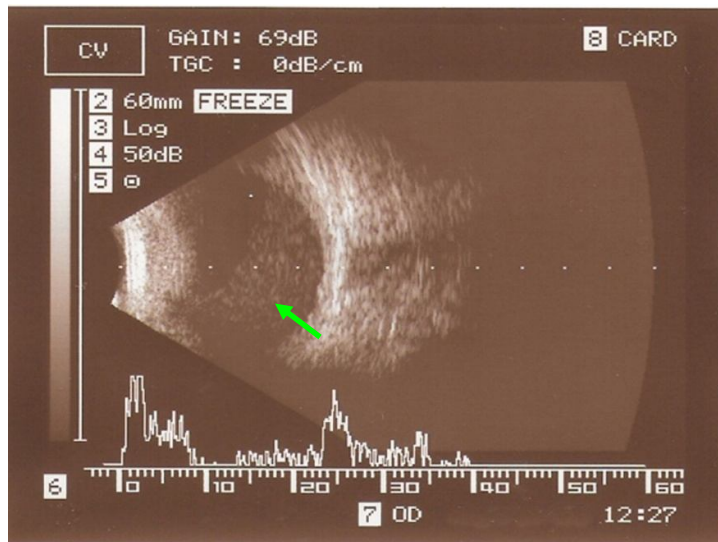


Fig. 3b: Ultrasonography of the globe shows vitreous hemorrhage in high gain sensitivity (arrow)

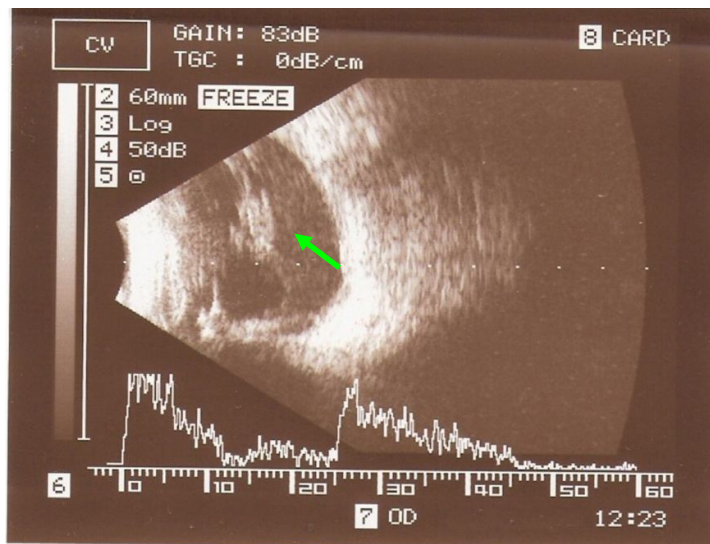


Fig. 4a: Ultrasonography of the globe shows asteroid hyalosis in low gain sensitivity (arrow)

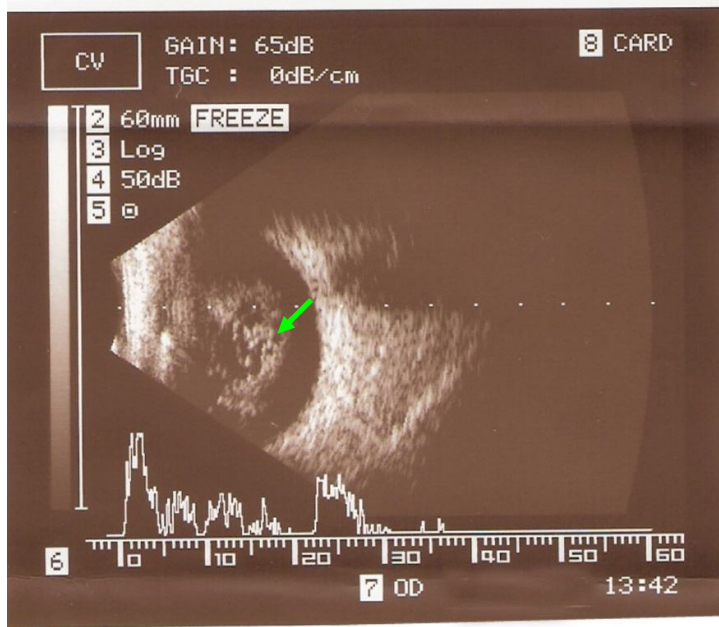


Fig. 4b: Ultrasonography of globe shows asteroid hyalosis in high gain sensitivity (arrow)

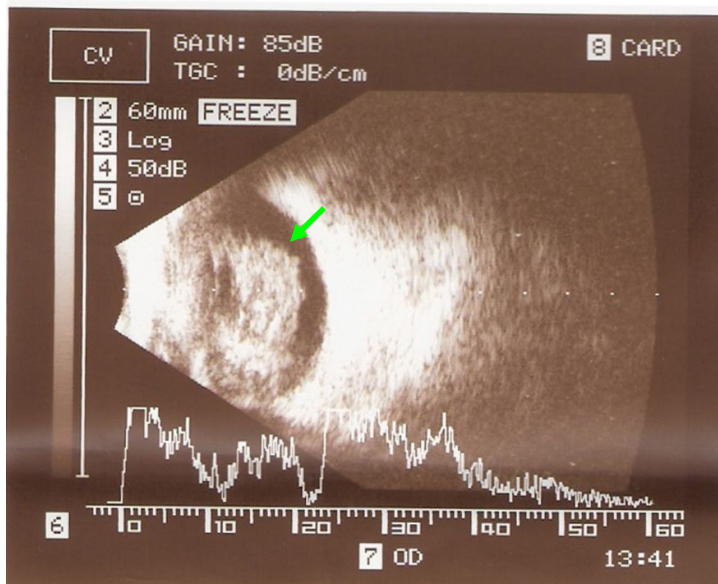




Fig. 5: Ultrasonography of the globe shows intra ocular foreign body with vitreous hemorrhage (arrow)

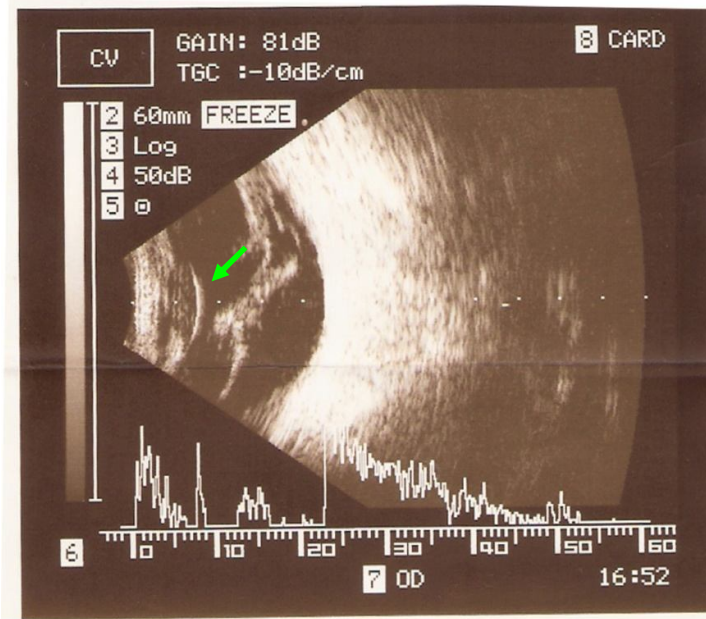


Fig. 6: Ultrasonography of the globe shows posterior staphyloma

