

# A case report on total pancreatic lipomatosis: An unusual entity

**Ravinder Kumar,  
Abhishek Bhargava,  
Gagan Jaiswal**

Department of Radiodiagnosis, Geetanjali Medical College and Hospital, Geetanjali University, Udaipur, India

**Address for correspondence:**

Dr. Ravinder Kumar,  
Department of Radiodiagnosis, AG-1,  
Geetanjali Medical Campus, Manvakhera,  
Udaipur - 313 002, Rajasthan, India.  
Phone: +919571218953.  
E-mail: kundu19@yahoo.co.in

**WEBSITE:** ijhs.org.sa

**ISSN:** 1658-3639

**PUBLISHER:** Qassim University

## ABSTRACT

Total pancreatic lipomatosis (PL) is an unusual entity of pathologic significance and speculative origin. It refers to complete replacement of pancreatic parenchyma by fat cells. Fat replacement may vary from mild fatty infiltration to massive replacement of the pancreas by adipose tissue, resulting in malabsorption syndrome due to pancreatic insufficiency. We present a case of a 60-year-old elderly woman with atypical abdominal complaints, diabetes mellitus, weight loss, and steatorrhea. Abdominal computed tomograms were diagnostic of PL. Magnetic resonance imaging verified this impression. The patient improved clinically after the 8-week trial of high-dose oral pancreatic enzyme replacement therapy. There is a marked reduction of steatorrhea and weight gain. This case report focuses on pathophysiology, diagnosis, and treatment guidelines of PL.

**Keywords:** Computed tomography, magnetic resonance imaging, malabsorption, pancreatic lipomatosis, steatorrhea

## Introduction

Pancreatic lipomatosis (PL) is also known as adipose atrophy of pancreatic parenchyma. The pancreas may appear normal or may be massively enlarged, resulting in a condition known as lipomatous pseudohypertrophy.<sup>1</sup> This case report highlights the potential diagnostic value of radiological examination in the evaluation of this unusual condition.

## Case Report

A 60-year-old woman presented with a 2-month history of chronic diarrhea, decreased appetite, loss of weight, and occasional edema. She described her stools as “frothy and mucus retained.” She complained of bloating, flatulence, and on and off vague upper abdominal pain for 6 months. Six months before presentation, the patient was diagnosed with type 2 diabetes mellitus and was on an insulin therapy regimen. She had no relevant history of familial illness. Physical examination revealed no organomegaly or palpable abdominal mass; however, pallor and mild tenderness in epigastrium were present. Respiratory and cardiovascular system examination was unremarkable. Routine blood tests, renal and liver function tests were normal. Ascitic fluid tap revealed clear transudate. Biochemical investigations showed raised serum amylase and serum pancreatic lipase levels (516 U/L and 912 U/L; normal values 0-200 U/L and 0-190 U/L, respectively), consistent with pancreatitis. Ultrasound abdomen revealed hyperreflective pancreas with increased echogenicity. Axial unenhanced computed tomography (CT) scan at the level of

the pancreas showed low-attenuation hypodense fat density area completely replacing head, body, and tail of pancreas. The density of the pancreatic parenchyma had uniformly decreased to the same level as that of the surrounding fatty tissue (Figure 1a). Contrast-enhanced CT of abdomen revealed atrophic pancreas, completely replaced by fat (attenuation value = -76 HU) with no demonstrable normal pancreatic parenchyma. The entire pancreatic parenchyma was absent, and only a contrast-enhancing net-like shadow was visible (Figure 1b). There was no calcification, intrapancreatic mass or dilatation of pancreatic duct, intrahepatic biliary radicals, or common bile duct. On the basis of abdominal computed tomogram assessment, a provisional diagnosis of total PL, secondary to pancreatitis, was made. To confirm the diagnosis, magnetic resonance cholangiopancreatography (MRCP) was performed. On MRCP, the cross-sectional images revealed high signal intensity in the corresponding location of the pancreas, consistent with fatty infiltration (Figure 1c). The common bile duct, the main pancreatic duct and duct of Wirsung were normal and clearly seen (Figure 1d).

Figure 1a shows axial unenhanced CT scan at the level of pancreas shows low-attenuation hypodense fat density area completely replacing head, body, and tail of pancreas. Figure 1b shows arterial phase contrast-enhanced axial CT section demonstrate atrophic pancreas with total fat replacement. The entire pancreas has low attenuation value (HU = -76). As shown in Figure 1c, axial T2-weighted (T2W) MR image which show high-signal intensity in the corresponding location of the pancreas, consistent with fatty infiltration. Signals in

pancreatic region is similar to mesenteric fat, however, ductal structures still evident (Figure 1d).

Fecal fat analysis established malabsorption. Reduced fecal concentration of elastase, decreased the output of insulin and glucagon led to the diagnosis of exocrine pancreatic insufficiency, resulting from total PL. Optimal management guidelines aimed at control of pain, dietary deficiencies, chronic pancreatitis, and improvement of maldigestion. Conservative treatment of low-fat diet was started. Modern pancreatin of preparation was given for the treatment of maldigestion and steatorrhea. The supplementation of 25,000-40,000 IU of lipase per meal for 8 weeks reduced the steatorrhea to <15 g fat per day. The patient improved clinically as there is a marked reduction of steatorrhea and weight gain.

## Discussion

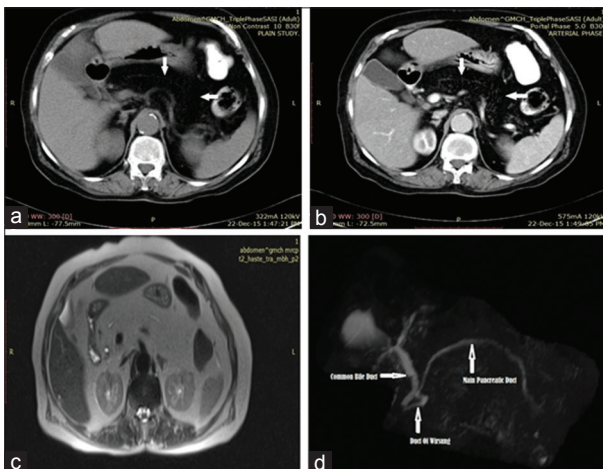
Fat replacement may vary from mild fatty infiltration to massive replacement of the pancreas by adipose tissue, resulting in malabsorption syndrome due to pancreatic insufficiency.<sup>2</sup>

However, etiopathogenesis of this benign entity is not well understood. It is common in elderly, obese individuals and in some patients with congenital abnormalities such as Shwachman-diamond syndrome and cystic fibrosis. Other conditions related to diffuse fatty replacement of pancreas include diabetes mellitus, steroid therapy, Cushing's syndrome, chronic pancreatitis, hemochromatosis, and malnutrition.<sup>2-4</sup> Most cases remain asymptomatic, and only some rare extreme degrees of lipomatosis may be associated with a significant depression of pancreatic function. However, in our case, the patient presented with atypical abdominal pain, malabsorption, and diabetes mellitus due to exocrine and endocrine pancreatic insufficiency. This situation is well established by fecal fat analysis and associates malabsorption of nutrients and clinical symptoms comprising chronic diarrhea, steatorrhea, and weight loss. Nevertheless, only a few case reports have

suggested a direct relation between PL and exocrine pancreatic insufficiency,<sup>5</sup> and further functional studies are necessary to establish this association. The typical islets of Langerhans are paradoxically noteworthy for being resistant to PL. On the contrary, decreased output of insulin and glucagon (our patient is a diagnosed case of Diabetes mellitus) led to the diagnosis of exocrine pancreatic insufficiency, resulting from total PL. Although this entity is associated with the presence of diabetes mellitus; it is not specifically due to the disease itself. Diffuse fatty infiltration of the pancreas also correlates with the presence of diabetes mellitus or acquired or hereditary pancreatitis.<sup>6</sup> In our case also, elevated serum P-amylase and serum pancreatic lipase levels (3 times above the upper limit of normal), signaled toward the diagnosis of pancreatitis.

Sonographic findings are often nonspecific and inconclusive, and such assessment does not usually allow definitive characterization. The overlying bowel gas causes obscuration of the pancreas. Furthermore, the fatty change results in hyperreflective pancreas with increased echogenicity, making its differentiation difficult from normal retroperitoneal fat. In 80% of cases, abdominal computed tomograms (CT) and MR imaging can provide additional diagnostic information where clinical and sonographic features are inconclusive, unusual, or indeterminate. Unenhanced CT can reliably diagnose diffuse PL as it shows more specific fat density in pancreatic bed and has negative attenuation value of pancreatic parenchyma replaced by the fat. However, on postcontrast images, the normal pancreatic parenchyma entrapped between adipose tissue may show contrast enhancement simulating a true mass.<sup>7</sup> When the condition is severe, the pancreas will have the same signal intensity, and density as the mesenteric fat and thus may not be identifiable. MRI has advantage over CT in confirming the presence of uneven fatty replacement of the pancreas. MRI reveals a variable-sized pancreas with high signal intensity.<sup>2</sup> A characteristic loss of signal intensity on the opposed-phase T1W gradient-echo image as compared with corresponding in-phase image confirms the presence of microscopic lipid within the focal pancreatic mass detected on CT. MRCP/endoscopic retrograde cholangiopancreatography ERCP demonstrates the status of pancreatic duct and the biliary tree. Selective pancreatic angiography is especially useful in differentiating PL from dorsal agenesis by showing the pancreatic circulation. In our case also, CT abdomen showed atrophic pancreas with complete pancreatic parenchymal absence and fatty replacement (Figure 1a and b) MRI verified this impression (Figure 1c and d). The recognition of this pancreatic adipose atrophy syndrome by the radiologist is important since it represents a benign pancreatic condition that responds to adequate enzyme replacement therapy.

Conditions that have clinical pictures similar to that of PL include: Pseudoagenesis (atrophy of the corpus and the tail of the pancreas secondary to chronic pancreatitis); carcinoma of the head of pancreas (proximal atrophy of the gland); pancreas divisum (the absence of fusion or incomplete



**Figure 1: a-d** Density of the pancreatic parenchyma

fusion of the ventral and dorsal pancreas, mainly of the drainage ducts [Wirsung' and Santorini]); pancreatic pseudo lipodystrophy; pancreatic masses; and agenesis of the dorsal pancreas (ADP).<sup>2-5</sup> The differentiation between lipomatosis and pancreatic agenesis is important and is made on the basis of whether the ductal system is present (lipomatosis) or absent (agenesis). It is, therefore, crucial to obtain a careful medical history and to perform the appropriate imaging studies: Computed axial tomography (CT), MR pancreatogram (MR imaging [MRI], including MRCP) or ERCP to exclude the aforementioned differential diagnoses.

Optimal management guidelines aimed at improvement of maldigestion, dietary deficiencies, chronic pancreatitis, and control of pain. Oral pancreatic enzyme replacement therapy is used for the treatment of maldigestion. Insulin therapy regimen is used to control diabetes mellitus. Treatment success is defined by digestion of fat, improved body weight, and consistency of feces.

## Conclusion

The clinical presentation of total PL is usually insidious due to varying signs and symptoms and should be considered in the differential diagnosis of patients with malabsorption. CT and MRI including MRCP are easy, reliable, safe, and

effective imaging methods for establishing the diagnosis. The combination of low dietary modification with modern pancreatin preparation and lipase supplementation is the gold standard for treatment.

## References

1. Nakamara M, Katanda N, Sakalibara A, Okumura N, Kato K, Takeichi M, *et al.* Huge lipomatous pseudohypertrophy of the pancreas. *Am J Gastroenterol* 1979;72:171-4.
2. Kim KH, Kim CD, Ryu HS, Hyun JH, Chung JP, Chung JB, *et al.* Endoscopic retrograde pancreatographic findings of pancreatic lipomatosis. *J Korean Med Sci* 1999;14:578-81.
3. Patel S, Bellon EM, Haaga J, Park CH. Fat replacement of the exocrine pancreas. *AJR Am J Roentgenol* 1980;135:843-5.
4. Poddar U, Thapa BR, Sinha SK, Bhasin DK. Massive steatorrhea in a child due to isolated pancreatic hypoplasia. *Indian Pediatr* 2001;38:1298-300.
5. Anand R, Narula MK, Chaudhary V, Agrawal R. Total pancreatic lipomatosis with malabsorption syndrome. *Indian J Endocrinol Metab* 2011;15:51-3.
6. Altinel D, Basturk O, Sarmiento JM, Martin D, Jacobs MJ, Kooby DA, *et al.* Lipomatous pseudohypertrophy of the pancreas: A clinicopathologically distinct entity. *Pancreas* 2010;39:392-7.
7. Matsumoto S, Mori H, Miyake H, Takaki H, Maeda T, Yamada Y, *et al.* Uneven fatty replacement of the pancreas: Evaluation with CT. *Radiology* 1995;194:453-8.