

Hepatoprotective role of Legalon 70 against hydrogen peroxide in chickens

Samera M. Alkatib¹,
May K. Ismail²,
Alaa H. AlMoula¹,
Intesar R. Alkennany³

¹Department of Physiology, Biochemistry and Pharmacology, College of Veterinary Medicine, University of Mosul, Iraq, ²Department of Biomedical Sciences, Gulf Medical University, Ajman, United Arab Emirates, ³Department of Pathology, College of Veterinary Medicine, University of Mosul, Iraq

Address for correspondence:

Samera M. Alkatib, Department of Physiology, Biochemistry and Pharmacology, College of Veterinary Medicine, University of Mosul, Iraq.
E-mail: samar.alkatib@gmail.com

WEBSITE: ijhs.org.sa

ISSN: 1658-3639

PUBLISHER: Qassim University

Introduction

Liver is the key organ for several vital functions, it plays an abundant role in metabolism (carbohydrates, lipids, and proteins), in bile excretion, and in the detoxification of waste products.^[1] Acute and chronic liver diseases are an important cause of mortality in the world. Viral hepatitis B and C, alcoholic and nonalcoholic fatty liver, fibrosis, and hepatocellular carcinoma are the major liver diseases.^[2] Every form of liver damage causes changes in the membrane of the liver cells and in this way impairs the functions of liver.^[3] Medical therapies for many common liver disorders have limited efficacy and have the risk of side effects. This has led to increased dependence on the complementary and alternative medicine, especially herbal medicine due to its naturally sources and safer form of therapy.^[4,5]

Milk thistle is medical plant used for centuries in the treatment of liver diseases.^[6] Silymarin is the more important

ABSTRACT

Objectives: This study aimed at evaluating the effect of Legalon 70, a standard hepatic drug of silymarin, in reducing the toxic effects of hydrogen peroxide (H₂O₂) in broiler chickens.

Methods: Twenty Ross broiler chickens of 30-day old were divided into four groups, Group 1 control, received drinking tap water, Group 2 treated with 0.5% H₂O₂ in drinking water, Group 3 treated with 0.5% H₂O₂ and 3 mg/Kg Legalon 70 daily, and Group 4 treated with a single oral dose of 3 mg/Kg Legalon 70 daily. After 4 weeks of the treatment, chickens were killed and the serum collected for the measuring of liver functions parameters, and the liver tissues used for processing the histological examination.

Results: The results indicated that H₂O₂ treatment significantly elevated serum aspartate aminotransferase and alanine aminotransferase, and bilirubin level (direct and total) and decreased level of serum albumin comparing with control group. Treatment with Legalon 70 significantly reversed the H₂O₂-induced alteration and has positive effects on the liver functions parameters. Results of histopathology of H₂O₂-treated group showed severe vascular congestion, alveolar damage, and inflammatory cell infiltration, silymarin treatment blocked these changes and reduced the toxic effects of H₂O₂ toward liver cells.

Conclusion: We concluded that silymarin induces the liver function recovery and considered in the treatment of liver injury. Silymarin, a major component of milk thistle, has been used as a hepatoprotector.

Keywords: Hydrogen peroxide, Legalon 70, liver functions, silymarin

constituent in milk thistle seed and fruit.^[7] Silymarin is flavonolignan complex composed of four isomers: Silybin, isosilybin, silychristin, and silydianin.^[8] Silymarin complex acts as cell membrane stabilizer, protects and regenerates liver cells from toxins,^[9] and encourages the liver to clean itself of damaging substances such as alcohols, drugs, and heavy metals.^[10] Silymarin prevents lipid peroxidation in liver cells and able to increase the synthesis of ribosomal RNA by acting on RNA polymerase. Nowadays, silymarin preparations are available as Siliphos, Silicide, Phytosome, and Legalon 70 in the form of capsules or tablets and being tested in clinical trials for its therapeutic efficacy of hepatotoxicity.^[11]

Since the chickens are affected by many oxidants and toxic substances that are claimed to be the cause of liver damage which decreased growth rates, egg production, and increased the ability to other diseases. Hence, the present study was carried out to evaluate the protective effects of Legalon 70 against hydrogen peroxide (H₂O₂), a potent

hepatotoxic compound, by monitoring the liver functions and histopathological study in chickens.

Materials and Methods

Drug

Legalon 70, provided by MADAUS GmbH, 51101 KÖln, Germany, was used in this study (1-degree Legalon 70 contains 70 mg silymarin).

Animals

Twenty Ross broiler chickens of 1-day old were randomly divided into four groups of five chickens each. The chickens of each group were housed in the animal's house of Veterinary Medicine College, University of Mosul, in individual suspended stainless steel cages of environmentally controlled room, and the artificial light was supplied for 12 h away. Feed and water were supplied *ad libitum* throughout the experiment. The chickens were adapted for 30 days before treatment, then the chickens were treated for 4 weeks as follows: Group 1 normal control group fed with standard diet and drinking water, Group 2 treated with 0.5% H₂O₂ in drinking water,^[12] Group 3 H₂O₂-treated group and orally administrated 3 mg/Kg Legalon 70 single dose daily, and Group 4 orally administrated 3 mg/Kg Legalon 70 single dose daily. At the end of the treatment period, chickens were slaughtered by cutting the neck with a sharp knife, and 4–5 ml of blood is collected in a test tube. Samples and liver tissues were collected as well.

Biochemical assays

Blood samples were centrifuged, and the serum used for the measuring of albumin, total and direct bilirubin, alanine aminotransferase (ALT), and aspartate aminotransferase (AST). These tests were performed using kits provided by Biolab-Maizy-France. Portion of liver tissue in different groups was fixed in 10% neutral buffered formalin and embedded in paraffin wax. Sections were cut at 4–6 µm in thickness, stained with hematoxylin and eosin, and then viewed by light microscope for histopathological findings.

Statistical analysis

The data of different groups were expressed as mean ± standard deviation and statistically analyzed with SPSS 19 version using one-way analysis of variance. $P < 0.05$ was considered statistically significant.

Results

As shown in Table 1 and Figure 1, the albumin concentration was significantly lower after treatment with H₂O₂ in Group 2 compared with the control group ($P < 0.05$). Administration of Legalon 70 in Group 3 and Group 4, significantly increased the serum albumin level, compared to Group 2. Furthermore,

ALT as well as total and direct bilirubin levels are decreased significantly compared to Group 2. Of notice, AST serum level is not significantly decreased on treatment with Legalon 70 as shown in Table 1 and Figures 2-5.

Pathological findings

Control livers showed normal lobular architecture with central veins and radiating hepatic cords. The connective

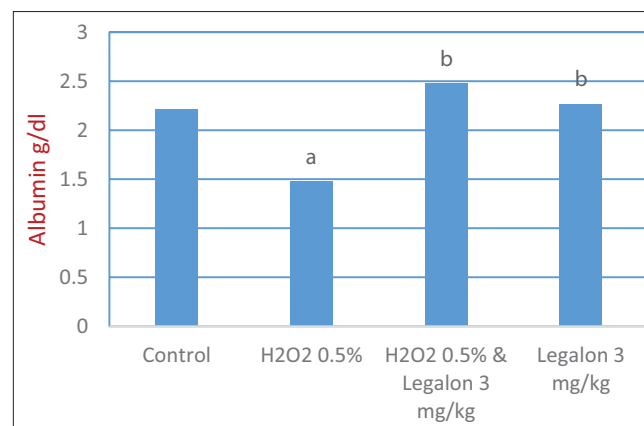


Figure 1: Effect of Legalon 70 on the serum albumin

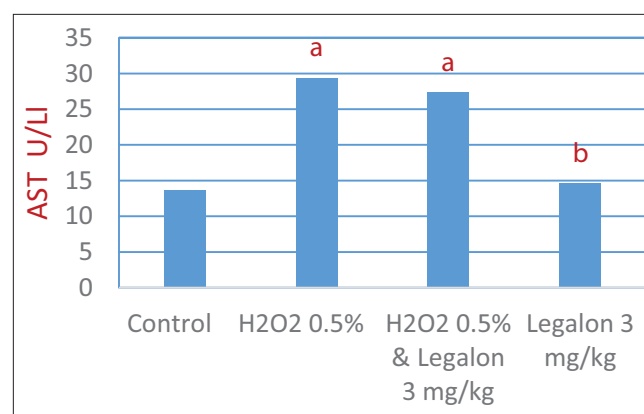


Figure 2: Effect of Legalon 70 on the aspartate aminotransferase activity

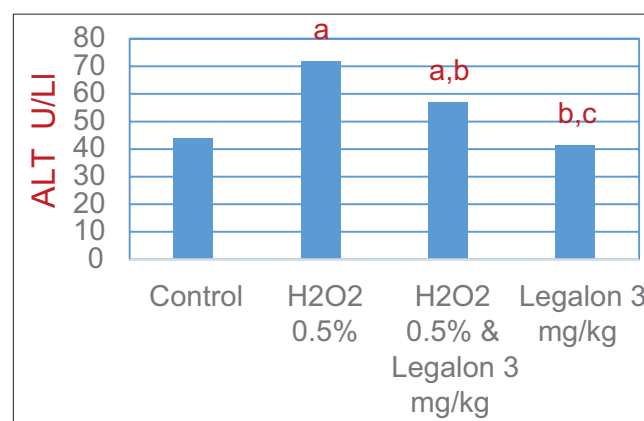
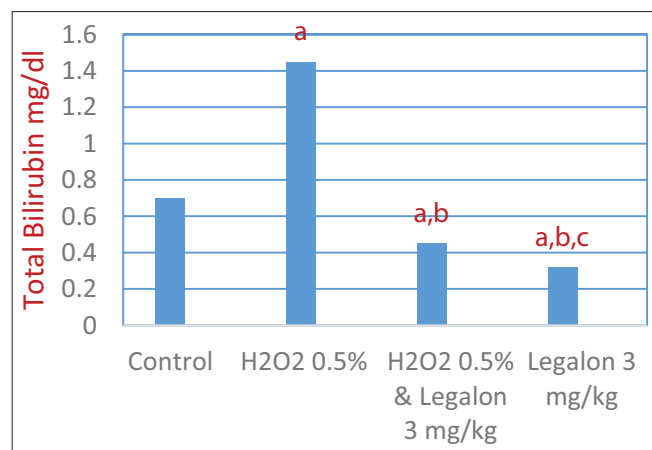
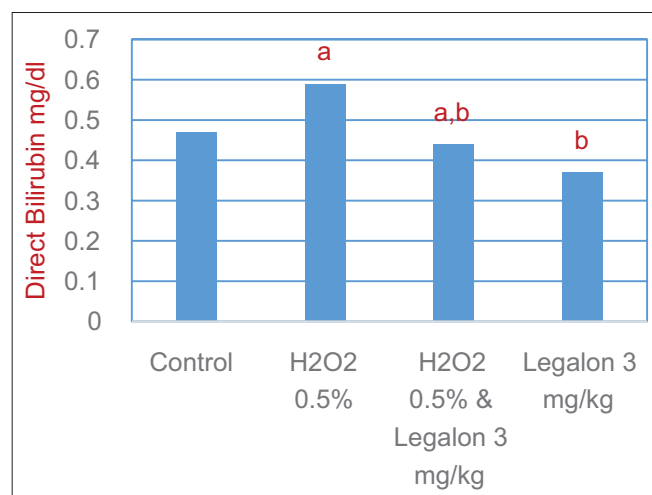


Figure 3: Effect of Legalon 70 on the alanine aminotransferase activity

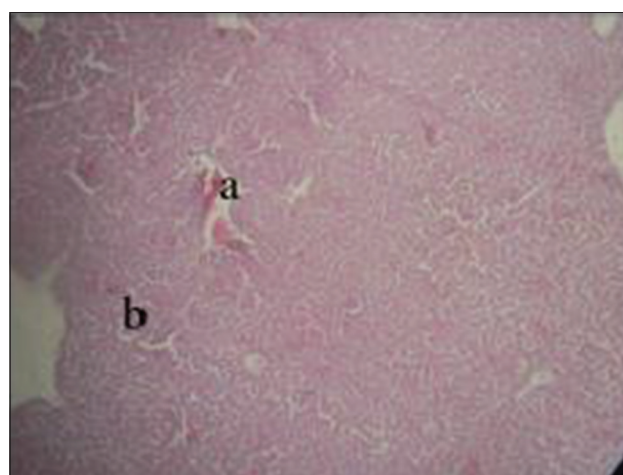
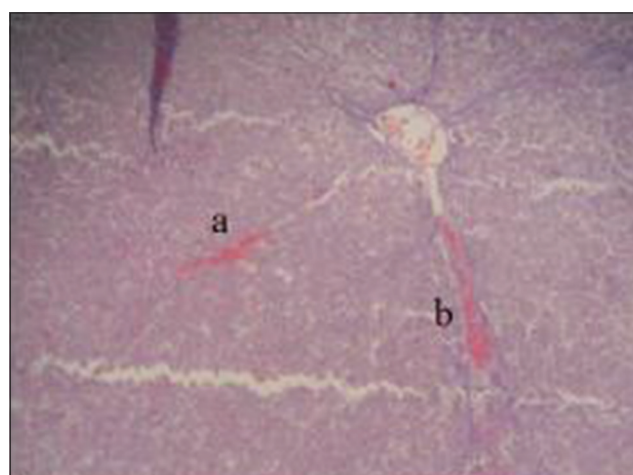
Table 1: Effect of Legalon 70 on the liver function for all groups in the study

Parameters of liver function	Group 1 control	Group 2 H ₂ O ₂ 0.5%	Group 3 H ₂ O ₂ 0.5% and Legalon 3 mg/kg	Group 4 Legalon 3 mg/kg
Albumin g/dl	2.21±0.07	1.48±0.17 ^a	2.48±0.26 ^b	2.27±0.08 ^b
AST U/L	13.60±1.77	29.40±2.42 ^a	27.40±2.54 ^a	14.60±2.60 ^b
ALT U/L	44.00±2.77	71.80±2.70 ^a	57.00±5.98 ^{a, b}	41.40±1.67 ^{b, c}
Total bilirubin mg/dl	0.70±0.07	1.45±0.18 ^a	0.45±0.06 ^{a, b}	0.32±0.06 ^{a, b, c}
Direct bilirubin mg/dl	0.47±0.09	0.59±0.05 ^a	0.44±0.05 ^{a, b}	0.37±0.41 ^b

Data are expressed as means±SD. AST: Aspartate aminotransferase, ALT: Alanine aminotransferase. ^aSignificant difference compared to control group ($P<0.05$). ^bSignificant compared to H₂O₂-untreated group ($P<0.05$). ^cSignificant compared to H₂O₂-treated group ($P<0.05$). SD: Standard deviation

**Figure 4:** Effect of Legalon 70 on the total bilirubin**Figure 5:** Effect of Legalon 70 on the direct bilirubin

tissue (C.T.) was demonstrated as a very thin layer of collagenous fiber around the central vein. Minimal C.T. was also observed at the portal areas. Administration of 0.5% H₂O₂ in drinking water daily for 30 days caused pathological changes represented by sinusoidal dilation and congestion together with midzonal vacuolar degeneration, lobular disarray, multifocal areas of aggregation of mononuclear inflammatory cells, and suffer cells hypertrophy were seen [Figure 6]. Livers of chickens treated with 3 mg/kg Legalon

**Figure 6:** Chickens liver section showed sinusoidal congestion (a) and dilatation (b) in group received 0.5% H₂O₂ alone (H and E ×10)**Figure 7:** Chickens liver section showed vacuolar degeneration (a) and sinusoidal congestion (b) in group treated with Legalon 70 (Group 4) (H and E ×10)

70 daily for 30 days showed progressive severe congested and dilated sinusoid and central vein associated with vacuolar degeneration [Figures 7 and 8]. Chickens treated with H₂O₂ and 3 mg/kg of Legalon 70 for 30 days showed congestion of blood vessels and swelling of hepatocyte in addition to converted vacuolar degeneration, also suffer cells hypertrophy [Figures 9 and 10].

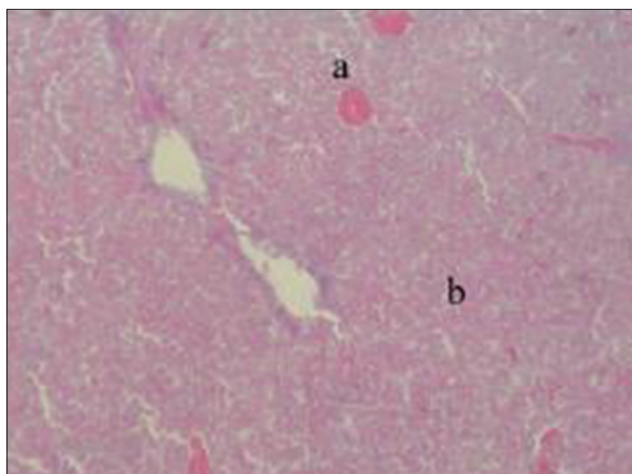


Figure 8: Chickens liver section showed sinusoidal dilation and congestion (a) and vacuolar degeneration (b) in group treated with Legalon 70 (Group 4) (H and E $\times 10$)

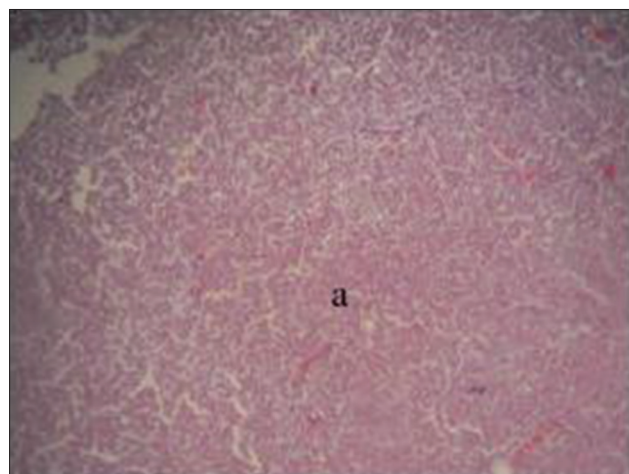


Figure 9: Chickens liver section showed sinusoidal dilation and congestion (a) in group treated with hydrogen peroxide and Legalon 70 (Group 3) (H and E $\times 10$)

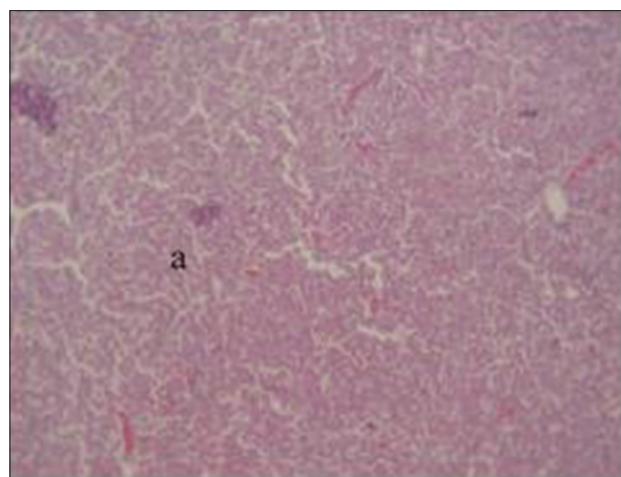


Figure 10: Chickens liver section showed converted in vacuolar degeneration (a) in group treated with hydrogen peroxide and Legalon 70 (Group 3) (H and E $\times 10$)

Discussion

H₂O₂ has been suggested to cause the generation of liver injury. In this study, H₂O₂ in drinking water leads to significant decrease in albumin concentration compared with control group; this result is with agreement to several studies which referred to the effect of oxidants and H₂O₂ on liver toxicity and impairing of liver function.^[13,14] Standard drug of silymarin (Legalon 70) increases the level of albumin in Groups 3 and 4 compared with H₂O₂-induced group; this could be due to the protective effect of silymarin and its ability to stimulate the regeneration of hepatocytes which can lead to increase protein synthesis and improve the liver functions.^[15] The study of Mansour *et al.*^[16] showed that the increase in the albumin level is due to the role of silymarin in the protection of hepatocytes through its antioxidant and scavenging effects of free radicals. The antioxidant properties of silymarin are due to the polyphenolic constituents of its structure which play an important role in the protection of hepatocytes and improvement of liver function, leading to increase protein synthesis.^[17]

H₂O₂ treatment lead to elevation the serum ALT, AST levels and bilirubin (direct and total) which indicated cellular damage and loss of the functional integrity of cells membranes, and that is due to the release of these enzymes from the cytoplasm into the blood. Serum ALT, AST, and bilirubin are the most important in the diagnosis of hepatic damage because these enzymes located in the cytoplasm and hence released into the circulation after liver damage.^[18,19] Treatment with Legalon 70 significantly reduced the activities of serum ALT and AST and serum bilirubin, this indicates that silymarin prevents the liver damage by maintaining the integrity of the plasma membrane and thus inhibits the release of enzymes through membrane.^[20]

The present results are in agreement with published findings by others who reported that treatment with silymarin provides protection against the oxidants that induced alteration in liver such as in the present study.^[21-23] Yadav *et al.*^[24] reported that silymarin able to regeneration of hepatic cells, thus protecting against membrane fragility and decrease the leakage of the marker enzymes and bilirubin into the circulation. Furthermore, Shaker *et al.*^[25] explained the antioxidant property of silymarin and its flavolignan can prevent the formation of lipid peroxidation in the liver cells due to its properties as free radical scavenger leading to stabilization of the cell membranes and decreased enzymes levels toward normalization.

The antioxidant property of silymarin makes it useful in the prevention of organ-specific toxicity related to induction of oxidative stress;^[26] hence, in this study, the histopathological changes induced by H₂O₂ elucidate many lesions such as vacuolar degeneration (fatty changes), congestion, and infiltration of mononuclear inflammatory cells. These results agree with Alkennany.^[112] Vacuolation of hepatocytes may attribute to either hydroid degeneration caused by more absorption of water into the metabolically disturbed cells or

fatty degeneration caused by lipid abundance in such cells. Legalon 70 protects liver tissue against oxidative stress through reduction the fatty changes. Similar results indicated that silymarin can protect liver tissue against oxidative stress with different intoxication in cats.^[27] Moreover, Legalon 70 showed that sinusoids dilation and congestion take place due to alterations in hepatic blood flow that affects rates of drug metabolism.^[28] This study also showed that silymarin (Legalon 70) was able to protect the animals from oxidative stress produced in the liver by H₂O₂. On the other hand, cell swelling, vacuolar degeneration occurs due to the ability of H₂O₂ to cause injury of hepatocytes through its effect on the mitochondrial membrane and to inhibit mitochondrial respiration which leads to swelling of mitochondria and causes leakage of ALT and AST.^[29]

Conclusion

The results of this study suggested that Legalon 70 has protective effects against H₂O₂-induced hepatotoxicity in chickens by its ability to balance the liver function status.

References

- Bishop ML, Fody EP, Schoeff LE. Clinical Chemistry. 5th ed. Ch. 10. North Carolina: Lippincott Williams and Wilkins; 2005. p. 255.
- Diehl AM. Liver disease in alcohol abusers: Clinical perspective. *Alcohol* 2002;27:7-11.
- Rouach H, Fataccioli V, Genti M, French SW, Morimoto M, Nordman R. Effect of chronic ethanol feeding on lipid peroxidation and protein oxidation in relation to liver pathology. *Hepatology* 1997;25:351-5.
- Bean P. The use of alternative medicine in the treatment of hepatitis C. *Am Clin Lab* 2002;21:19-21.
- Strader DB, Bacon BR, Lindsay KL, La Breque DR, Morgan T, Wright EC, *et al.* Use of complementary and alternative medicine in patients with liver disease. *Am J Gastroenterol* 2002;97:2391-7.
- Dixit N, Baboota S, Kohli K, Ahmamd S, Silymarin AJ. A review of pharmacology aspects and bioavailability enhancement approaches. *Indian J Pharmacol* 2007;39:172-9.
- Tumova L, Rimakova J, Tuma J, Dusek J. *Silybum marianum* in vitro-flavonolignan production. *Plant Soil Environ* 2006;52:454-8.
- Kim N, Graf T, Sparacno C, Wani M, Wall M. Complete isolation and characterization of silybin from milk thistle (*Silybum marianum*). *Org Biomol Chem* 2003;1:1684-9.
- Zheleva A, Tolekova A, Zhelev M, Uzunova V, Platiokonava A, Godzheva V. Free radical reactions might contribute to sever alpha amanitin hepatotoxicity a hypothesis. *Med Hypotheses* 2007;69:361-7.
- Morazzoni P, Bombardelli E. *Silybum marianum* (*Carduus marianus*). *Fitoterapia* 1995;66:3-42.
- Wen Z, Dumas T, Schrieber S, Hawk R, Fried M, Smith P. Pharmacokinetics and metabolic profile of free, conjugated and total silymarin flavonolignans in human plasma after oral administration of milk thistle extract. *Drug Metab Dispos* 2008;36:65-72.
- Al-Kennany E. Study on the Capability of Hydrogen Peroxide to Induce Athermanous Lesions Experimentally in Chickens Ph.D. Thesis. University of Mosul; 1998.
- Kiruthiga P, Beema S, Karutha P, Arun S, Govindu S, Pandima D. Protective effect of silymarin on erythrocyte hemolysate against benzo (a) pyrene and exogenous reactive oxygen species (H₂O₂) induced oxidative stress. *Chemosphere* 2007;68:1511-8.
- Aziz B. Effect of hydrogen peroxide induced oxidative stress on epididymal sperm of mice. *Iraqi J Vet Sci* 2000;13:61-5.
- Sambath K, Sivakumar T, Sivakumar P, Nethaji R, Vijayabasker M, Perumal P, *et al.* Hepatoprotective and *in vivo* antioxidant effects of *Careya arborea* against carbon tetrachloride induced liver damage in rats. *Int J Mol Med Adv Sci* 2005;1:418-23.
- Mansour H, Hafez F, Fahmy N. Silymarin modulates cisplatin-induced oxidative stress and hepatotoxicity in rats. *J Biochem Mol Biol* 2006;39:656-61.
- Murray NM, Joseph N. Encyclopedia of Natural Medicine. Rocklin, California: Prima Publishing; 1991. p. 82.
- Weber L, Boll M, Stampfl A. Hepatotoxicity and mechanism of action of halo alkanes: Carbon tetrachloride as a toxicological model. *Crit Rev Toxicol* 2003;33:105-36.
- Raja S, Ahmed K, Kumar V, Mukerjee, K, Bandyopadhyay A, Mukerjee P. Antioxidant effect of *Cytisus* scenarios against carbon tetrachloride treated liver injury in rats. *J Ethnopharmacol.* 2007;109:41-47.
- Pradeep K, Mohan CV, Gobianand K, Karthikeyan S. Silymarin modulates the oxidant-antioxidant imbalance during diethyl nitrosamine induced oxidative stress in rats. *Eur J Pharmacol* 2007;560:110-6.
- Tedesco D, Steidler S, Galletti S, Tameni M, Sonzogni O, Ravarotto L. Efficacy of silymarin-phospholipid complex in reducing the toxicity of aflatoxin B1 in broiler chickens. *Poult Sci* 2004;83:1839-43.
- Judith G, Hadiey T, Rotstein D, Perrin S, Gerhardt L, Beam J, *et al.* Effects of dietary milk thistle on blood parameters, liver pathology, and hepatobiliary scintigraphy in white corneous pigeons (*Columba livia*) challenged with B1 aflatoxin. *J Avian Med Surg* 2009;23:114-24.
- Wellington K, Jarvis B. Silymarin. A review of its clinical properties in the management of hepatic disorders. *BioDrugs* 2001;15:465-89.
- Yadav N, Pal A, Shankar K, Bawankule D, Gupta A, Darokar M, *et al.* Synergistic effect of silymarin and standardized extract of *Phyllanthus amarus* against CCL4-induced hepatotoxicity in *Rattus norvegicus*. *Phytomedicine* 2008;15:1053-61.
- Shaker E, Mahmoud H, Mnaa S. Silymarin. The antioxidant component and *Silybum marianum* extracts prevent liver damage. *Food Chem Toxicol* 2010;48:803-6.
- Varzi H, Esmailzadeh S, Morovvati H, Avizeh R, Shahriari A, Givi M. Effect of silymarin and Vitamin E on gentamicin induced nephrotoxicity in dogs. *J Vet Pharmacol* 2007;30:477-81.
- Valenzuela A, Garrido A. Biochemical bases of the pharmacological action of the flavonoid silymarin and of its structural isomer silybin. *Biol Res* 1994;27:105-12.
- Lappin M. Feline Internal Medicine Secrets. 2nd ed. Philadelphia, PA: Hanleg Belfus Inc.; 2001. p. 158-61.
- Towson E, Allu-Eldeen A, E-Moghazy M. P53 and Bcl-1 expression in response to beldonen induced liver cell injury. *Toxicol Ind Health* 2011;27:711-8.