

Total synovectomy and total knee arthroplasty in old patient with pigmented villonodular synovitis – A case report

Abdul-Aziz Almaawi¹,
Fahad M. AlSuwayeh²

¹Department of Orthopedic Surgery, College of Medicine, King Saud University, Riyadh, Saudi Arabia, ²Department of Orthopedics, College of Medicine, King Saud University, Riyadh, Saudi Arabia

Address for correspondence:

Fahad M. AlSuwayeh, Department of Orthopedics, College of Medicine, King Saud University, Riyadh, Saudi Arabia. E-mail: fahad.alsuwayeh@gmail.com

WEBSITE: ijhs.org.sa

ISSN: 1658-3639

PUBLISHER: Qassim University

ABSTRACT

Pigmented villonodular synovitis (PVNS) is a rare and benign lesion of unknown cause. Most cases reported in adult age patients. The diagnosing of PVNS is more difficult in old age patients and might be confused with osteoarthritis. This article reviews detailed history, examination, and investigations of 79 years-old male patient with 5 years history of right knee pain and deformity. The patient was diagnosed with PVNS, and total synovectomy was performed, followed by constrained total knee arthroplasty. The present report aimed to highlight that the total synovectomy with total knee arthroplasty is a viable option with the advantage of favorable outcome in treating patients with PVNS associated with advanced osteoarthritis.

Keywords: Knee arthroplasty, old patient, pigmented villonodular synovitis, synovectomy

Introduction

Pigmented villonodular synovitis (PVNS) is a rare proliferative disease that affects 1.8 patients per million population.^[1] PVNS was first described by Jaffe *et al.* in 1941, as a benign lesion affecting the synovium.^[2] The disease usually affects the synovium of large synovial joints, most commonly the knee joint. However, it can also affect other joints such as the hip, elbow, and ankle. PVNS can also affect bursal membranes and tendon sheaths.^[3] The prevalence of the disease is highest among people aged 20–50 years; however, it can occur at any age.^[4] There is no consensus regarding the etiology of this disease; some suggest chronic inflammation,^[5] several others suggest neoplastic origin,^[6] lipid metabolism, trauma, and recurrent hemorrhage as a possible etiology.^[7]

PVNS possesses marked variability of disease expression according to the location.^[8,9] that can be localized, diffuse, and extra-articular. In the localized type, the synovium appears lobulated, whereas in the diffuse type, the entire synovium of the joint is involved. The extra-articular type is also known as giant cell tumor of the tendon sheath. Early diagnosis of PVNS is crucial, and establishing proper management of this disease can prevent a catastrophic result, which is a terminal degenerative joint disease.^[10-12]

Case Presentation

A 79-year-old man presented to our clinic with a chief complaint of right knee pain and deformity for 5 years, with

an increase in severity over time. The pain affected his daily activities and led to multiple emergency room visits. He did not get any improvements with conservative treatment including medication and physiotherapy. On presentation, he had no history of trauma or infection in his right knee.

On examination, there was severe varus deformity of the right knee. The range of motion for the right knee was 30°–100° and the distal neurovascular examination was normal. Initial X-ray radiographs showed severe degenerative changes in both knees, but it was more severe on the right side [Figures 1 and 2]. Options were discussed with the patient and he was keen to get his symptoms improved. Complex primary total knee arthroplasty was considered after weighing the risks and benefits of such an intervention. Informed consent was obtained.

Preoperative blood work was performed, and his hemoglobin level was found to be 127 mg/L. Prophylactic antibiotics were administered, and we used a single dose of cefazolin 1 g preoperatively and three doses postoperatively.

Intraoperatively, after preparing the patient and applying pneumatic tourniquet, a medial parapatellar approach was performed on the right knee. The gross appearance of the synovium was found to be pigmented and dark brown. Since this appearance is not typical of synovitis presenting with chronic osteoarthritis, PVNS was suspected and a sample from the synovium was sent to the histopathology laboratory.

Based on the histopathology report, the patient was diagnosed with PVNS. Therefore, the surgical total synovectomy was performed, followed by constrained total knee arthroplasty.

Postoperatively, the patient reached a range of motion from 0° to 120°. No surgical drain was used. His postoperative hemoglobin levels on the 1st and 4th days were 103 mg/L and 98 mg/L, respectively. The patient had the usual postoperative protocol in terms of rehabilitation, anticoagulants, antibiotics, and pain medications [Figure 3].

Following the surgery, the patient was evaluated using the Knee Society Score for a total of 19 months, with the first follow-up at the 3rd week postoperatively. The wound healed with no wound-related complications, and his right knee's range of motion was 0°–90°. In the 6th week, his pain and range of motion improved; he started walking using a cane and doing his exercises at home.

Discussion

PVNS is an uncommon lesion that has progressive and destructive patterns with benign features.^[1] This lesion most commonly affects large joints with a two-third of cases

occurring in the knee joints, followed by the hip joints (16%), ankle joints (7%), and wrist, shoulder, and elbow joints (2% each). It can also affect the bursal membranes and tendon sheaths.^[1,3] Moreover, it has a higher prevalence in adults aged 20–50 years.^[13,14] The present case is a 79-year-old male and most of the cases in the old ages were confused with osteoarthritis and thus explained why he was complaining of joint pain for 5 years at his right knee without diagnosis.^[1]

PVNS was classified by Granowicz and Mankin into localized and diffuse types.^[15] Extra-articular PVNS was also described as giant cell tumor of the tendon sheath, which is commonly found in the hand but also found along the tendons of the foot and ankle.^[10] It was believed that the diffuse and localized PVNS were two different diseases, but in 1941, Jaffe *et al.* recognized that they were two different presentations of the same disease.^[2] Diffuse-type PVNS insidiously infiltrates the synovial cavity lining, which will eventually lead to erosion of the bone. Patients with diffuse PVNS present with insidious pain and/or swelling for a long period, and examination may reveal a firm swelling, diffuse tenderness, effusion, or restricted range of motion.^[16,17] The present case experienced diffuse type of PVNS with infiltration of the synovial cavity and bone erosion.

Conventional radiographs such as X-rays are usually not helpful in the diagnosis of PVNS, although they may show degenerative changes in the later stages.^[11] In contrast, magnetic resonance imaging can determine the extent and diagnosis of PVNS.^[12] The present case was in late stage, the radiological X-rays imaging showed severe degenerative changes in both knees, but it was more severe on the right side.

In the context of treatment, the treatment of choice is resection, using either an open technique or arthroscopy; the local recurrence can reach up to 56% in the diffuse form.^[4] The reason behind the recurrence, as suggested

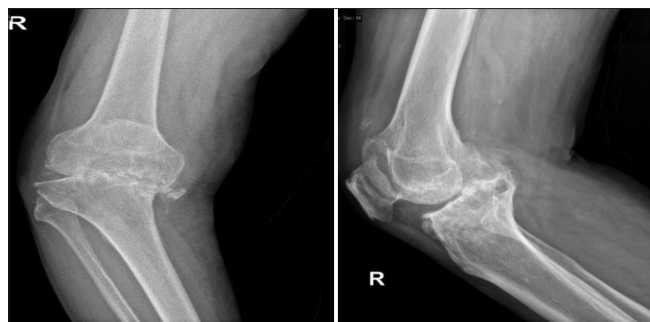

Figure 1: Severe degenerative changes Anteroposterior view (left side) and Lateral view (right side) of the right knee upon initial presentation

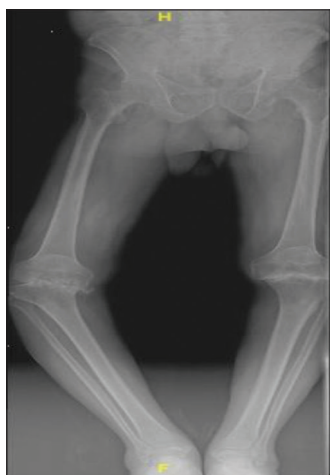

Figure 2: Full-length lower limb centigram upon initial presentation

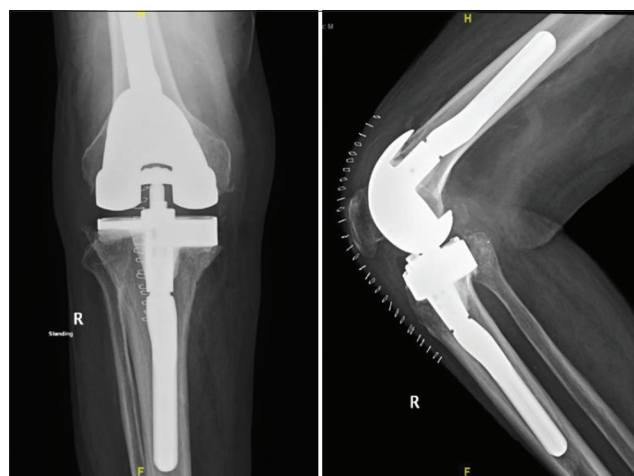


Figure 3: Anteroposterior view (left side) and Lateral view (right side) of the right knee postoperatively

by several authors, is incomplete resection, as radical resection of the abnormal tissue is an important aspect of treating this disease.^[18] Localized PVNS in the knee joint can be successfully excised using arthroscopy with a recurrence rate in the range of 24%.^[19,20] As the diffuse form of PVNS tends to recur postarthroscopic excision with a 55% recurrence rate, open synovectomy is preferable.^[16,20] Open synovectomy has a recurrence rate ranging from 8% to 18%, and the dual approach significantly reduces the recurrence rate. The present patient underwent surgical total synovectomy, followed by constrained total knee arthroplasty.

Conclusion

In conclusion, total synovectomy with total knee arthroplasty is a suitable option for treating PVNS in patients with advanced osteoarthritis. Further, studies are warranted to assess the comorbidities of PVNS synovium resection in total knee arthroplasty settings.

Authors' Declaration Statements

Patient Consent

Written consent was taken from the patient for research publication.

Availability of data and materials

Data that support the findings of this study are available from the corresponding author and shall be produced upon reasonable request.

Competing interests

The authors declare no competing of interest.

Funding statement

None.

Authors' Contributions

FHD conceived and designed the study, conducted research, provided research materials, and collected and organized the data. AMW analyzed and interpreted the data. FHD wrote the initial and final drafts of the article and provided logistic support. All authors have critically reviewed and approved the final draft and are responsible for the content and similarity index of the manuscript.

Acknowledgment

None.

References

1. Myers BW, Masi AT, Feigenbaum SL. Pigmented villonodular synovitis and tenosynovitis: A clinical epidemiologic study of 166 cases and literature review. *Medicine* 1980;59:223-38.
2. Jaffe HL. Pigmented villonodular synovitis, bursitis and tenosynovitis. *Arch Pathol* 1941;31:731-65.
3. Aurégan JC, Klouche S, Bohu Y, Lefèvre N, Herman S, Hardy P. Treatment of pigmented villonodular synovitis of the knee. *Arthroscopy* 2014;30:1327-41.
4. Kim SJ, Shin SJ, Choi NH, Choo ET. Arthroscopic treatment for localized pigmented villonodular synovitis of the knee. *Clin Orthop Relat Res* 2000;379:224-30.
5. Sakkars R, De Jong D, Van der Heul R. X-chromosome inactivation in patients who have pigmented villonodular synovitis. *JBJS* 1991;73:1532-6.
6. Choong PF, Willen H, Nilbert M, Mertens F, Mandahl N, Carlen B, *et al.* Pigmented villonodular synovitis: Monoclonality and metastasis—a case for neoplastic origin? *Acta Orthop Scand* 1995;66:64-8.
7. Singh R, Grewal D, Chakravarti R. Experimental production of pigmented villonodular synovitis in the knee and ankle joints of rhesus monkeys. *J Pathol* 1969;98:137-42.
8. Qingtian CH, Mengyuan L, Yuanchen M, Junxing L, Qiujian Z. Multifocal pigmented villonodular synovitis in adult: A case report and review of the literature. *Arch Med* 2015;7:1-3.
9. Muramatsu K, Iwanaga R, Tominaga Y, Hashimoto T, Taguchi T. Diffuse pigmented villonodular synovitis around the ankle. *J Am Podiatr Med Assoc* 2018;108:140-4.
10. Saxena A, Perez H. Pigmented villonodular synovitis about the ankle: A review of the literature and presentation in 10 athletic patients. *Foot Ankle Int* 2004;25:819-26.
11. Júnior LF, Cenni MH, Leal RH, Teixeira LE. Artroplastia total do joelho em paciente com sinovite vilonodular pigmentada forma difusa. *Rev Bras Ortop* 2017;52:616-20.
12. Bassetti E, Candreva R, Santucci E. Pigmented villonodular synovitis of the knee: A case report. *J Ultrasound* 2011;14:167-9.
13. Dorwart R, Genant H, Johnston W, Morris J. Pigmented villonodular synovitis of synovial joints: Clinical, pathologic, and radiologic features. *Am J Roentgenol* 1984;143:877-85.
14. Oda Y, Takahira T, Yokoyama R, Tsuneyoshi M. Diffuse-type giant cell tumor/pigmented villonodular synovitis arising in the sacrum: Malignant form. *Pathol Int* 2007;57:627-31.
15. Granowitz SP, Mankin HJ. Localized pigmented villonodular synovitis of the knee: Report of five cases. *JBJS* 1967;49:122-8.
16. Stevenson JD, Cribb G, Cool P. Pigmented villo-nodular synovitis of joints and tendon sheaths. *Orthop Trauma* 2012;26:273-9.
17. Sharma H, Jane MJ, Reid R. Pigmented villonodular synovitis of the foot and ankle: Forty years of experience from the Scottish bone tumor registry. *J Foot Ankle Surg* 2006;45:329-36.
18. De Ponti A, Sansone V, Malcherè M. Result of arthroscopic treatment of pigmented villonodular synovitis of the knee. *Arthroscopy* 2003;19:602-7.
19. Chin KR, Barr SJ, Winalski C, Zurakowski D, Brick GW. Treatment of advanced primary and recurrent diffuse pigmented villonodular synovitis of the knee. *JBJS* 2002;84:2192-202.
20. Ogilvie-Harris D, McLean J, Zarnett M. Pigmented villonodular synovitis of the knee. The results of total arthroscopic synovectomy, partial, arthroscopic synovectomy, and arthroscopic local excision. *J Bone Joint Surg Am* 1992;74:119-23.