

Symptomatic hemorrhagic pleural effusion: A rare presentation of ovarian hyperstimulation syndrome: A Case Report

Ali Alaraj, MBBS, SB-Med

College of Medicine, Qassim University, Saudi Arabia

Abstract

Isolated unilateral pleural effusion is uncommon presentation of ovarian hyperstimulation syndrome. The pathogenesis of this syndrome involves an increased permeability of ovarian capillaries and mesothelial vessels triggered by the release of vasoactive substances by the ovaries under human chorionic gonadotropin stimulation. Physicians should consider this potentially life-threatening diagnosis in all patients who undergo ovarian hyperstimulation. This case highlights a rare clinical manifestation of isolated hemorrhagic pleural effusion associated with ovarian hyperstimulation

Key words: ovarian hyperstimulation syndrome, pleural effusion.

Correspondence:

Dr. Ali Alaraj

College of Medicine

Medicine Department

Qassim University

Email: al_alaraj@hotmail.com

Tel No: +966503935564

Introduction

Pharmacological ovarian stimulation, a well established therapeutic procedure in the field of infertility, has been widely used in the last decade. Ovarian hyperstimulation syndrome (OHSS), a serious iatrogenic complication of ovulation induction treatment, is associated with substantial morbidity and occasional mortality.⁽¹⁾ The hallmark of OHSS is increase in capillary permeability resulting in a fluid shift from intravascular space to the third space compartments.⁽²⁾ In most cases the clinical manifestations of OHSS are self-limiting and resolve spontaneously within a few days, provided that appropriate supportive measures are taken.⁽¹⁾ Symptoms range from mild abdominal pain, diarrhea and nausea to severe disease characterized by ascites, rapid weight gain, hemodynamic instability, tachypnea and oliguria. Due to the increased use of therapeutic strategies for infertility, the pulmonary complication of this syndrome should be suspected on clinical grounds and identified early to allow more appropriate diagnosis and management. Isolated pleural effusion either unilateral or bilateral is a rare presentation in this condition.

I'm reporting a case of hemorrhagic pleural effusions that developed after ovarian hyperstimulation for in vitro fertilization (IVF).

Case Report

A 26 year old healthy woman with primary infertility was seen in IVF clinic. Fourteen days prior to presentation she was started on controlled ovarian stimulation for IVF. She received follicle stimulating hormone (FSH) and human menopausal gonadotropin according to IVF protocol. Five days after oocyte retrieval, she presented to our emergency department with progressive shortness of breath, associated with lower abdominal pain and nausea. On physical examination, her heart rate was 110 beat/min, blood pressure 100/70 mm Hg and O₂ saturation 90% breathing room air. There was reduced breath sounds and stony dullness at the right lower chest. Abdomen was soft and non tender with no evidence of organomegaly. The rest of clinical examination was unremarkable.

Investigations revealed slightly raised WBC count with no left shift and normal hemoglobin and platelet count. Renal, hepatic and

coagulation profiles were within normal range. Serum protein was 57g/l and lactate dehydrogenase was 279u/l. Urine and serum pregnancy tests were negative. The arterial blood gas result showed pH 7.37 PO₂ 70 mm Hg, PCO₂ 34mm Hg.

Chest X-Ray (Figure 1) revealed right pleural effusion, a chest computed tomography (CT) (Figures 2&3) showed a massive right side pleural effusion associated with compression collapse of right lung. The maximum density of pleural effusion was 148 HU suggesting a hemorrhagic nature of effusion.

In view of her symptoms pleural fluid was drained by inserting a pigtail catheter under ultrasound guidance. Pleural fluid analysis showed an exudative effusion with a protein 43g/l, lactate dehydrogenase 145 u/l, glucose 6.6 mmol/l, white blood cell count 95/cu.mm, red blood cell count 860/cu.mm. The cytology of pleural fluid was negative for malignancy. Fluid gram stain, culture and acid fast stain were negative.

Doppler ultrasonography of both legs showed no evidence of deep vein thrombosis. A Spiral CT chest after drainage of pleural effusion was negative for the Pulmonary Embolism. She was labeled to have pleural effusion due to OHSS after excluding all the secondary causes. She was treated symptomatically with intravenous fluids and supportive care. She improved symptomatically and was discharged in stable condition. A chest X-ray prior to discharge showed minimal effusion.

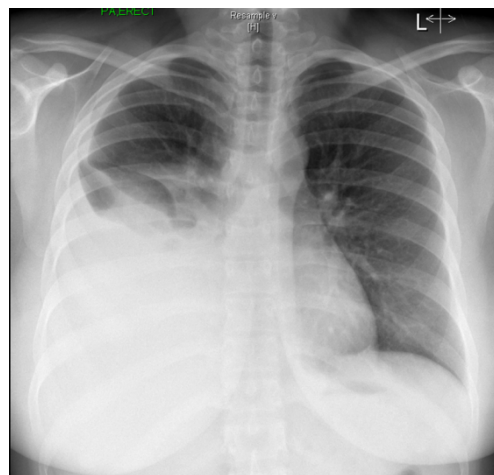


Figure 1. Chest X-ray showing large right sided pleural effusion.

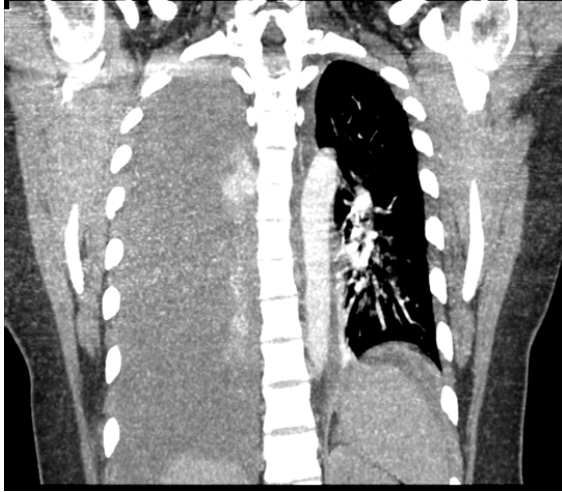


Figure 2. CT Coronal section showing massive right sided pleural effusion with collapse of the right lung

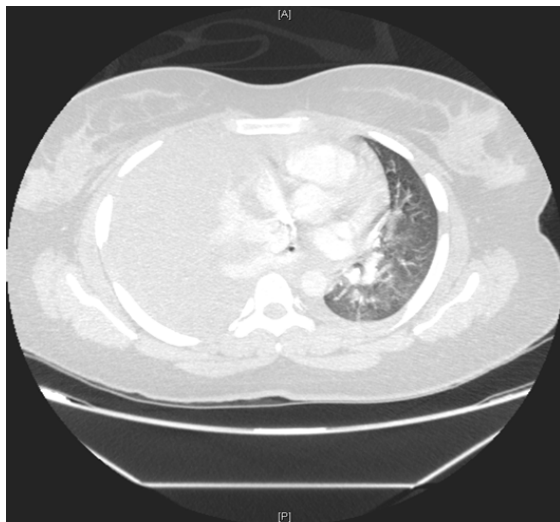


Figure 3. CT chest showing a massive right side pleural effusion associated with collapse of the right lung and mediastinal shift.

Discussion

Ovarian hyperstimulation syndrome is defined as an iatrogenic complication of ovarian stimulation. It can be a serious complication of "In vitro fertilization" with significant morbidity.⁽³⁾

The underlying mechanism of OHSS involves an increased permeability of ovarian capillaries and mesothelial vessels triggered by

the release of vasoactive substances by the ovaries under HCG stimulation.⁽³⁾ The pathogenesis of OHSS is generally believed to be the overproduction or altered expression of vasoactive substances of ovarian origin that are critical for follicle release or neovascularization of the developing corpus luteum.⁽⁴⁾

The predisposing factors believed to be polycystic ovary syndrome, younger age, lean body habitus, higher doses of exogenous gonadotropin and previous episodes of OHSS.⁽⁵⁾

Pulmonary complications of OHSS include pneumonia, Adult Respiratory Distress Syndrome, pulmonary embolism and pleural effusion.⁽⁶⁾ In a retrospective review of 130 patients with severe OHSS (defined as massive ascites/hydrothorax, hemodynamic instability, oliguria, anasarca, liver dysfunction and hemoconcentration), 38 (29%) were found to have pleural effusions. Of these 71% pleural effusions were unilateral and none of them were hemorrhagic.⁽⁶⁾

Another study showed 5 out of 22 patients with severe OHSS had pleural effusion.⁽⁴⁾ Pleural fluid is typically accompanied by marked ascites. However, isolated pleural effusion without ascites is not common.⁽⁷⁾ Pleural effusion in OHSS is almost always exudative. Hemorrhagic pleural effusion is very rare and has been reported in only one case report in English Literature.⁽⁸⁾

Conclusion

This case highlights a rare pulmonary presentation of Ovarian Hyperstimulation Syndrome. Due to the increased use of hormonal therapies for infertility, internists should be familiar with this potentially life-threatening complication of in vitro fertilization treatment.

References

1. Whelan GJ, Vlahos NF. The ovarian hyperstimulation syndrome. *Fert Sterl.* 2000; 73: 883-896
2. Goldsman, MP, Pedram A, Dominguez CE, Ciuffardi I, Asch RH. Increase capillary permeability induced by human follicular fluid: a hypothesis for an ovarian origin of hyperstimulation syndrome. *Fertil Steril* 1995 ;63:268-72

3. Roden, S, Juvin K, Homasson J, Israel-Biet D. An uncommon etiology of isolated pleural effusion. *Chest* 2000; 118:256-258
4. Levin, MF, Kaplan BR, Hutton LC. Thoracic manifestations of ovarian hyperstimulation syndrome. *Can Assoc Rad J* 1995;46:23-26
5. Garrett C, Gaeta T. Ovarian hyperstimulation syndrome: Acute dyspnea in a young woman. *Am J Emerg Med* 2002;20:63-64
6. Abramov Y, Elchalal U, Schenker J. Pulmonary manifestations of severe ovarian hyperstimulation syndrome: a multicenter study. *Fertil Steril.* 1999;71:645-651
7. Beji, O, Brahmi N, Thabet H, et al. Compressive pleural effusion after ovarian hyperstimulation syndrome—a case report and review. *Fertil Steril.* 2008; 89(6): e1-e3. 1826
8. Halvorson SA, et al. Thoracic endometriosis unmasked by ovarian hyperstimulation for in vitro fertilization. *J Gen Intern Med* 2012; 27(5):603–7