

## **Therapeutic Efficacy of Hysterosalpingography with Special Reference to Application of Hydrostatic Pressure During the Procedure**

**Mehboob Hussain, Saleh Al Damegh, Amin Tabish,**  
*College of Medicine, Qassim University, Saudi Arabia*

### **Abstract:**

**Background :** In the majority of infertile females, cause lies within the fallopian tubes. The causes for tubal obstruction include tubal endometriosis, chlamydial and tuberculous infections, salpingitis, due to previous tubal approach, previous tubal pregnancy, peritubal adhesions due to previous appendectomy, ovarian, uterine or adnexal operations. Other less important but easily treatable significant causes include tubal obstruction due to debris, fine adhesions or even unexplained tubal spasm. The later group can be managed with selective fallopian tube catheterization. Proximal tubal obstruction is seen in 10-20% of HSG examinations. The purpose of this study was to treat the infertility due to proximal fallopian tube obstruction with application of hydrostatic pressure during hysterosalpingography (HSG) technique.

**Methods :** A study of consecutive hundred women of 18-30 years (mean age=24 years) who were clinically suspected of proximal fallopian tube obstruction (FTO) or unexplained infertility were included in this study. Women with other organic causes were excluded from the study. All the selected women underwent for HSG examination within 10 days of the menstrual cycle (3-4 days after the bath) by applying 10 days rule and with the application of hydrostatic pressure using water soluble contrast medium during the procedure. Women with successful opening of fallopian tubes (47%) after the application of hydrostatic pressure were followed for 3-6 months for the pregnancy.

**Results :** The fallopian tubes were patent in 57 (57%) women and appeared obstructed in 43 (43%) females (33 unilateral and 10 bilateral). With application of hydrostatic pressure during HSG technique, 25 (47%) fallopian tubes in 22 women reveal prompt opening while 28 tubes in 21 women remain blocked. The rate of successful conception was observed in 6 (24%) women within 3-6 months after the procedure.

**Conclusion :** Application of hydrostatic pressure during the HSG examination offers a promising technique for the management of minimal proximal fallopian tube obstructions due to debris, fine adhesions and even in unexplained tubal spasm. Therefore, being minimally invasive and cost-effective, this technique may be adopted in all the suspected proximal fallopian tube obstruction or unexplained infertility, especially prior to selective fallopian tube catheterization (FTC), laparoscopy and laparotomy.

### **Correspondence:**

*Mehboob Hussain  
Department of Radiology  
College of Medicine, Qassim University.  
E-mail: moby\_hussain@yahoo.com*

## Introduction

The prevalence of infertility is 8 – 15 % world wide. In almost 1/3 of cases causes are within the females, in other 1/3 cases causes are within the males and in remaining 1/3 infertile couples, etiology remains unexplained.<sup>(1)</sup>

In the majority of infertile females, cause lies within the fallopian tubes. The causes for tubal obstruction include tubal endometriosis, chlamydial and tuberculous infections, salpingitis, due to previous tubal approach, previous tubal pregnancy, peritubal adhesions due to previous appendectomy, ovarian, uterine or adnexal operations.<sup>(2 - 10)</sup> Other less important but easily treatable significant causes include tubal obstruction due to debris, fine adhesions or even unexplained tubal spasm<sup>(11)</sup>. The later group can be managed with selective fallopian tube catheterization.<sup>(12)</sup> Proximal tubal obstruction is seen in 10-20% of HSG examinations.

Selective proximal fallopian tube catheterization is now considered the first line of treatment for the proximal fallopian tube obstruction in addition to availability of laparoscopy.<sup>(13)</sup> Most studies reveal up to 70-80% the proximal tubes opened by this technique and had 30% success rate for the conception.<sup>(14)</sup> However, there are always chances of tubal rupture, infection and more radiation hazard<sup>(15)</sup>. Moreover, the cost of selective FTC is also high as compared to HSG examination.<sup>(16)</sup> Therefore, there is a need for simpler technique which should be less invasive, cost effective and relatively safe. The purpose of this study was to introduce a simpler technique, especially with application of hydrostatic pressure with the use of water soluble contrast medium during the traditional HSG examination for treating the significant number of proximal tubal obstruction without additional cost and invasion.

## Methods

This study includes one hundred consecutive infertile women between 18- 30 years age (mean age= 24 years) who were referred to the department of radiology, Karachi x-rays and ultrasound, Karachi, Pakistan by the gynecologist and other clinicians between march 2003 - August 2004 for the diagnosis of possible tubal obstruction or unexplained infertility. All patients had undergone investigations like

serum hormonal levels and transvaginal sonography for exclusion of adnexal, ovarian and uterine causes of infertility. 59 women had primary infertility and 41 women had secondary infertility. The women with other causes of infertility like pelvic adhesions, tubal / ovarian endometriomas, previous tubal pregnancy, previous operative history or uterine causes were excluded from the study.

All selected patients were given appointment and briefed about the procedure. Written consent was obtained before the examination. Prophylactic capsule Doxycycline 100 mg BD were started 2 days prior to examination and continued for the next 3 days after examination. Injection hyoscine and were given in all patients just before examination for pain relief. All the examinations were selectively done within 10-15 days of the menstrual cycle (3-4 days after bath) depending upon the patient's menstrual cycle habits. The examinations were carried out under local anesthesia and lubrication provided by instillation of 2% lignocaine gel into the cervical canal. 13 women preferred for the general anesthesia for the fear of pain.

After all aseptic technique in lithotomy position, suitable size speculum were introduced by the female radiology resident doctors, cervix were visualized and cannulated either with Foleys catheter or cannula. After catheter or cannula retention in the uterine cavity, diluted (2 parts contrast medium and 1 part distilled water or normal saline) water soluble contrast medium was used (10- 30 cc). The injection of contrast medium was under fluoroscopic guidance and controlled drop by drop under the radiologist supervision. The films were taken for the uterine cavity, both fallopian tubes and for bilateral free peritoneal spills. Total fluoroscopic time for the normal examination was 14-38 seconds. Delayed films and modification of technique took slightly more fluoroscopic time up to 1.5 minutes. When any of the fallopian tube found obstructed, patient was positioned in lateral oblique position with head down position for few minutes (3-5 minutes) and hydrostatic pressure built by contrast medium was maintained. After 3-5 minutes, further injection of contrast medium opened the fallopian tubes in the majority of cases, only few cases required the repetition and maintaining of hydrostatic pressure for 2-3

times(rule of 3= waiting 3 minutes, attempted 3 times in one examination and pressure applied 3 times). In cases of rare bilateral tubal obstruction same rule applied for the contralateral side after opening of one tube. We did not encounter any complications during or after the procedure except intra-vasation in 2 cases which was due to early examination within 2 days of bath, but the procedure was furnished slowly with delayed techniques.

Total time for examination varied between 15- 55 minutes. Patients were observed in the department for 40-60 minutes for any complications or contrast medium reactions. Patients were reminded for continuation of antibiotics and warned for abstinence from sexual intercourse for 24-48 hours after the examination. Follow up on telephone or cell phone was taken up to 6 months for the conception of those patients whose fallopian tubes were opened after our modified technique.

### Results

The age group included was the most fertile period for any women between 18-30 years, majority had primary infertility.

100 selected cases suspected of tubal infertility or unexplained infertility underwent HSG examination, 57% women revealed normal HSG examinations ( both the fallopian tubes were found patent with free peritoneal spill of contrast medium Fig.1), 33% had unilateral tubal obstruction (Fig. 2)and 10% had bilateral tubal obstruction (Fig. 3) .

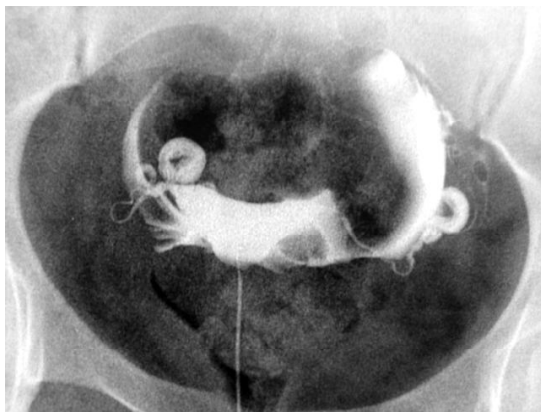


Fig. (1). Normal HSG examination.

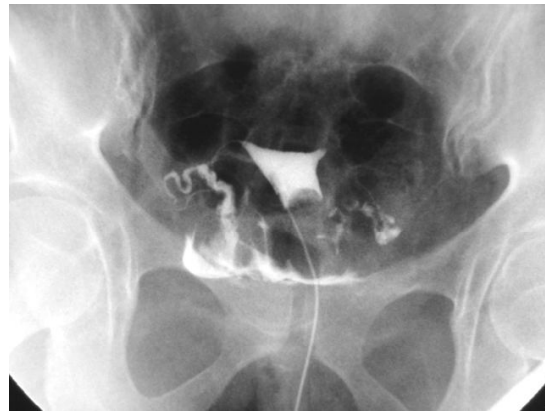

Fig. (2). Unilateral tubal obstruction.

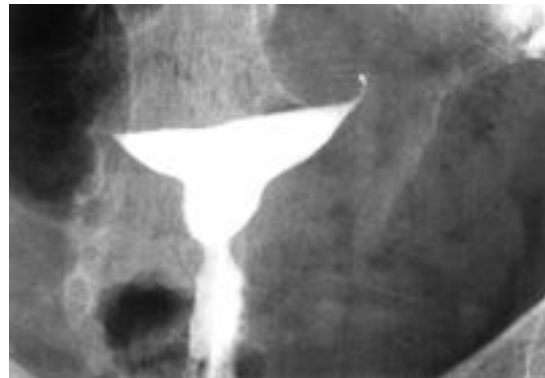

Fig. (3). Bilateral tubal obstruction.

Among 33 unilateral tubal obstruction, 15 tubes (46%) opened after the application of modified technique (Fig. 4), 2 tubes (6%) revealed hydrosalpinx and remained obstructed throughout the examination, 3 tubes (9%) revealed beaded appearance of the tube suggesting TB and remained closed. 13 (39 %) tubes did not showed any obstructed pathology on the HSG examination and attempts of modified technique failed to open the tubes.

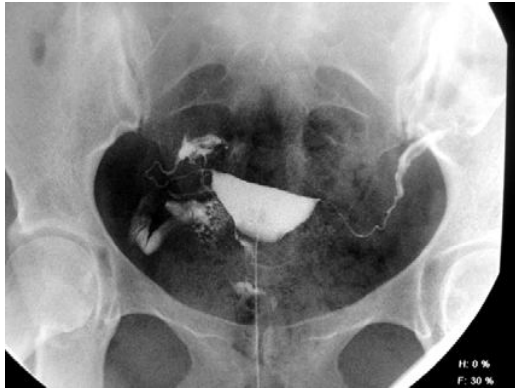


Fig. (4).Tubal opening after the application of hydrostatic pressure.

Among 10% bilateral tubal obstruction (Fig 5), 4% reveal unilateral opening of tube ( Fig 6 ), 3% revealed bilateral opening of the tubes and remaining 3% remained with bilateral tubal obstruction even with our modified technique.

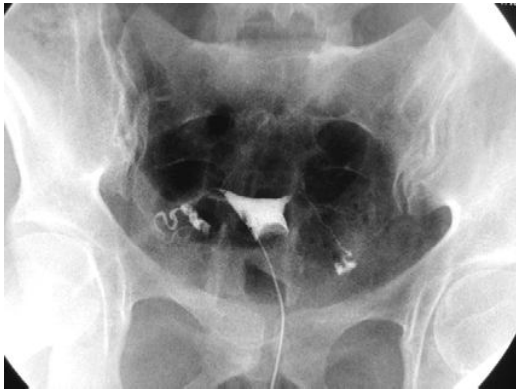

Fig. (5). Bilateral Tubal obstruction.

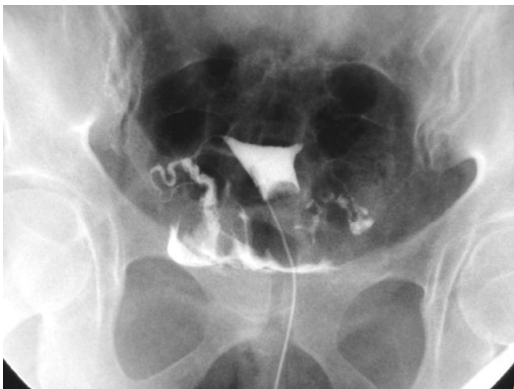

Fig. (6). Right fallopian tube opened after the application of hydrostatic pressure during

#### HSG examination.

This study revealed 53 tubal obstructions in 43 women. By our modified technique, 25 (47%) tubes become patent in 22 women and 28 tubes remain blocked in 21 women. Further follow up for 3-6 months of these women revealed pregnancy in 6 (24%) women.

#### Discussion

The diagnostic and therapeutic aspects of fluoroscopically guided HSG examination are closely related. To date selective proximal fallopian tube recanalization is considered the initial procedure for the treatment of selected fallopian tube obstructions.<sup>(17)</sup> Laparoscopy is the gold standard for the diagnosis and management of tubal infertility.<sup>(18)</sup>

Many studies reveal selective FTC has success rate of 71-92% with chances of pregnancy up to 30 %.<sup>(14)</sup> The complications observed in Selective FTC includes tubal rupture (2%), infection (1%) and tubal pregnancy (3%)<sup>(14)</sup>. Laparoscopy and dye instillation has a success rate of 35-40%, conception in 35-49% and complications in 2-6%.<sup>(18)</sup>

With the application of hydrostatic pressure during the traditional HSG examination has a success rate of 47% compared to 71-92% by selective FTC. The chances of pregnancy with our technique are 24% as compared to 30% by selective FTC. However, we did not meet any complications during or after the procedure up to 6 months follow up.

Although the treatment success and conception rates are relatively low with the application of hydrostatic pressure during the HSG examination but we assume that the benefits to the patient are more in terms of cost and risk. However, there are few pitfalls of our study like we did not follow the rest of the cases which appeared blocked or we couldn't follow for the long term and moreover this study was not on a large scale. Therefore, we recommend further large scale studies with more objectives for further refinement.

In conclusion, application of hydrostatic pressure during the HSG examination is a simple, safe and cost effective procedure. Its efficacy in the management of partially obstructed proximal fallopian tubes with fine adhesions, debris and unexplained tubal spasm has promising outcomes with no significant risk. Therefore, we recommend this technique should be adopted with the traditional HSG examination whenever it is needed.

### Acknowledgement

The authors are grateful to Dr .Syed Mehmood and Dr. Haji Haroon, Directors of Karachi x-rays and Ultrasound, Karachi, Pakistan and Radiology Resident Doctors (now radiologists) Dr. Rumasa, Dr. Asma, Dr. Shazia, Dr. Nighat and Dr. Farhana Sheikh

### References

- Eisenberg R. Obstetrical and gynecologic radiology. In: Eisenberg R, eds. Radiology, an illustrated history. St Louis, Mo: Mosby, 1992; 347-363.
- Hull M, Glazener C, Kelly NJ, Conway DI, Foster PA, Hinton RA, et al. Population study of causes, treatment, and outcome of infertility. *BMJ* 1985; 291: 1693-1697
- Akande VA, Hunt LP, Cahill DJ, Ford WCL, Jenkins JM. A cohort study of the prediction of Chlamydia infection causing subfertility, the value of treatment independent management and prognosis for pregnancy in 1119 women following laparoscopy. Presented at British Congress of Obstetrics and Gynaecology, Birmingham, 2001.
- Strandell, A., Bourne, T., Bergh, C. et al. (1999) The assessment of endometrial pathology and tubal patency: a comparison between the use of Ultrasonography and X-ray hysterosalpingography for the investigation of infertility patients. *Ultrasound Obstet. Gynecol.*, 14, 200–204
- Dmowski WP, Lesniewicz R, Rana N, Pepping P, Noursalehi M. Changing trends in the diagnosis of *endometriosis*: a comparative study of women with pelvic *endometriosis* presenting with chronic pelvic pain or infertility. *Fertil Steril* 1997; 67:238-243
- Chatman DL, Ward AB. *Endometriosis* in adolescents. *J Reprod Med* 1982; 27:156-160
- Koninckx PR, Ide P, Vandenbroucke W, Brosens IA. New aspects of the pathophysiology of *endometriosis* and associated infertility. *J Reprod Med* 1980; 24:257-260.
- Clement PB. Diseases of the peritoneum. In: Kurman RJ, eds. *Blaustein's pathology of the female genital tract*. 4th ed. New York, NY: Springer-Verlag, 1994; 660-680
- Scully RE, Young RH, Clement PB. Tumor-like lesions In: *Tumors of the ovary, maldeveloped gonads, fallopian tube, and broad ligament*. Washington, DC: Armed Forces Institute of Pathology, 1998; 430-434.
- Crum CP. The female genital tract. In: Cotran RS, Kumar V, Collins T, eds. *Robbins pathologic basis of disease*. 6th ed. Philadelphia, Pa: Saunders, 1999; 1057-1059.
- Hayashi N, Kimoto T, Sakai T, et al. Fallopian tube disease: limited value of treatment with fallopian tube catheterization. *Radiology* 1994; 190:141-143
- Thurmond AS, Novy MJ, Uchida BT, Rosch J. Fallopian tube obstruction: selective salpingography and recanalization. *Radiology* 1987; 163:511-514
- Kumpe DA, Zwedlinger SC, Rothbarth LJ, Durham JD, Albrecht BH. Proximal fallopian tube occlusion: diagnosis and treatment with transcervical fallopian tube catheterization. *Radiology* 1990; 177:183-187
- Amy S. Thurmond, Lindsay et.al. A review of selective salpingography and fallopian tube catheterization. *Radiographics*. 2000; 20: 1759-1768.
- Houston JG, Machan LS. Salpingitis isthmica nodosa: technical success and outcome of fluoroscopic transcervical fallopian tube recanalization. *Cardiovasc Interv Radiol* 1998; 21:31-35
- Thurmond AS, Uchida BT, Rosch J. Device for hysterosalpingography and fallopian tube catheterization. *Radiology* 1990; 174:571-572
- Maubon A, Rouanet JP, Cover S, Courtieu C, Mares P, Lopez FM. Fallopian tube recanalization by selective salpingography: an alternative to more invasive techniques?. *Hum Reprod* 1992; 7:1425-1438
- Goldstein DP, Decholnoky C, Emans SJ, Leventhal JM. Laparoscopy in the diagnosis and management of infertility. *J Reprod Med* 1989; 24:251-256.